



CURRENT MANAGEMENT OF BRAINSTEM GLIOMAS

Jallo GI[§] MD, Freed D[†] MS, Roonprapunt C[†] MD, PhD and Epstein F[†] MD

[§]Division of Pediatric Neurosurgery, Johns Hopkins Hospital, Baltimore, Maryland; [†]Division of Pediatric Neurosurgery, Institute for Neurology and Neurosurgery, Beth Israel Medical Center, New York, New York

ABSTRACT

Brainstem gliomas have historically been one of the most difficult pediatric cancers to treat. Tumors arising in the brainstem were once uniformly discounted as surgically unresectable lesions. Early neurosurgeons thought this location to be inoperable and fraught with disaster. The advent of computed tomography (CT), magnetic resonance imaging (MRI) and sophisticated neurophysiological monitoring techniques have significantly advanced the surgical treatment of these precarious lesions. Brainstem gliomas are now recognized as a heterogeneous group of tumors. They have been broadly classified into several categories depending upon the classification scheme. All these classification systems provide a framework to predict growth patterns, surgical resectability and overall prognosis for these heterogeneous tumors. These systems allow the surgeon to better differentiate low-grade tumors from the diffuse inoperable tumor type. The authors review the current management of brainstem tumors and their experience with brainstem gliomas over a 5 year period.

KEYWORDS: brainstem glioma • cervicomedullary • midbrain tumors • pontine glioma

The brainstem is defined as the midbrain, pons and medulla. Gliomas within the brainstem comprise 10-20% of all pediatric CNS tumors. In the United States, there are approximately 150-300 annual cases (8). Brainstem gliomas can occur at any age, although they generally present in childhood, with the mean age of diagnosis at 7 to 9 years (14, 43, 58). There is no gender predilection.

In the era before modern imaging, all brainstem gliomas were regarded as a single pathological entity, and the prognosis was considered uniformly poor. In 1969, Matson summarized that “regardless of specific histology, brainstem gliomas must be classified as malignant tumors since their location in itself renders them inoperable” (45). Pool was one of the first neurosurgeon to advocate surgery for certain brainstem tumors. He operated upon several children and reported a survival of 10 to 25 years (33). In the early 1980s, several neurosurgeons began reporting favourable surgical outcomes for

certain types of brainstem gliomas (10, 25, 27, 35, 57). Classification systems were then introduced which attempted to identify those tumors that benefited from surgery. These morphological systems further evolved with the advent of magnetic resonance imaging (MRI), thus helping to predict tumor behaviour and determine the best management algorithm for these tumors.

This article reviews the current literature and provides treatment options for brainstem gliomas. We also present our series of brainstem tumors treated at a single institution.

IMAGING AND CLASSIFICATION

Magnetic resonance imaging has emerged as the primary diagnostic modality for brainstem gliomas. MRI multiplanar images assist in the establishment of the tumor diagnosis, identification of tumor epicenter and prediction of its biological behavior. Astrocytomas are the most common intrinsic tumor of the brainstem. On histology, these tumors are fibrillary, in contrast to

cerebellar astrocytomas which are predominantly pilocytic. Other tumors which may arise in the brainstem include PNET (Primitive Neuroectodermal Tumors), lymphomas, gangliogliomas and oligodendrogliomas (21). Lymphoma is distinguished by its uniform enhancement after gadolinium administration. Although ependymomas typically extend into the fourth ventricle or cerebellopontine angle, they can occasionally resemble an intrinsic tumor of the brainstem since they may cause brainstem compression or appear to insinuate into the brainstem. Nonneoplastic lesions such as cavernous malformations, tuberculomas, and epidermoids have also been reported to arise within the brainstem. Additional imaging studies such as angiography, MRI spectroscopy or diffusion-weighted MRI sequences may be required for the uncertain diagnosis (23, 48). These imaging sequences have supplanted the need for stereotactic biopsy for certain brainstem gliomas (7).

Many classification schemes have been devised for brainstem tumors (Table 1). The earliest classifications relied on computed tomography and surgical observations. More recent classification schemes include MRI sequences. All these systems categorize the tumor by epicenter (diffuse or focal) or imaging characteristics. The simplest classification divides these tumors into two groups, either focal or diffuse regardless of tumor epicenter. The more complex schemes subdivide these tumors by location, growth pattern ('focality'), presence of hydrocephalus or hemorrhage, and growth pattern.

DIFFUSE BRAINSTEM GLIOMA

Diffuse gliomas are the most commonly encountered tumor of the brainstem accounting for 58-75% of all tumors (5, 27). On T1-weighted MRI scan, they appear hypointense with indistinct margins, reflecting the infiltrative nature of these high grade lesions (Figure 1). Diffuse gliomas of the brainstem are generally greater than 2 cm in size at time of presentation. They are characterized by diffuse infiltration and swelling (or hypertrophy) of the brainstem. The epicenter of the lesion is usually the pons, however rostral or caudal tumor extension is not unusual. These diffuse gliomas are distinguished from focal tumors by their indiscrete hyperintensity on T2-

weighted imaging. Gadolinium enhancement can be variable and has no prognostic implication (30). These diffuse gliomas are typically malignant fibrillary astrocytomas (Grade III or IV).

FOCAL TUMORS

Focal tumors are defined as demarcated lesions of the brainstem found in either the midbrain, pons or medulla. These focal tumors may be solid or cystic and they always have clear, distinct borders on MRI (Figure 2). The tumor size and characteristics are similar on both T1 and T2 sequences because of the relative lack of infiltration and edema. Tumor enhancement following gadolinium administration may be variable, but uniform enhancement is suggestive of a juvenile pilocytic astrocytoma. These focal tumors are mostly benign (Grade I or II) lesions, however anaplastic gangliogliomas and PNETs have been reported (1).

EXOPHYTIC TUMORS

Dorsal exophytic brainstem gliomas are a group of tumors that arise from the subependymal glial tissue (Figure 3). The bulk of the tumor resides within the fourth ventricle which accounts for the relatively late onset of symptoms. MRI reveals a well-demarcated lesion with similar T1-hypointensity and T2-hyperintensity signal characteristics.

On histology, these tumors are almost always low-grade gliomas. They tend to grow along paths of least resistance (into the fourth ventricle and into cisterns) rather than infiltrate the brainstem (36). Most of these exophytic tumors will enhance with gadolinium, and can be difficult to distinguish from ependymomas or choroid plexus papillomas (13). In our experience, exophytic tumors that grow laterally and ventrally into the brainstem are higher-grade tumors as compared to those exophytic tumors that project dorsally into the fourth ventricle.

CERVICOMEDULLARY TUMORS

Cervicomedullary brainstem gliomas are similar to intramedullary spinal cord gliomas (Figure 4). The epicenter of these tumors may be either in the medulla or cervical spinal cord. On MRI, these tumors show mixed low and intermediate signal intensity within the solid part of

TABLE 1
Classification Systems for Brainstem Tumors

Author, year	Classification System	System based on
Epstein, 1985	Intrinsic diffuse focal cervicomedullary Exophytic Anterolateral into cerebellopontine angle Posterolateral into brachium pontis Posterior into fourth ventricle Disseminated Positive cytology Positive myelography	CT
Epstein, 1986	Diffuse Focal Circumscribed mass less than 2 cm, no edema Cervicomedullary	CT, MRI and Surgical Observation
Stroink, 1986	Group I - dorsal exophytic glioma Group IIa - intrinsic brainstem tumors hypodense, no enhancement Group IIb - intrinsic brainstem tumors hyperdense, contrast enhancing, exophytic Group III - focal cystic tumor with contrast enhancement Group IV - focal intrinsic isodense, contrast enhancing	CT
Barkovich, 1991	Location Midbrain, pons, medulla Focality Diffuse or focal Direction and extent of tumor growth Degree of brainstem enlargement Exophytic growth Hemorrhage or necrosis Evidence of hydrocephalus	MRI
Albright, 1996	Focal Midbrain, Pons (dorsal exophytic pontine glioma), Medulla Diffuse	MRI
Fischbein, 1996	Midbrain Diffuse, focal, tectal Pons Diffuse, focal Medulla Diffuse, focal, dorsal exophytic	MRI
Choux, 1999	Type I - intrinsic tumor, diffuse, hypodense on CT, low intensity in T1-weighted images, with no significant enhancement Type II - intrinsic and focal tumor, which may be solid or cystic Type III - exophytic tumor, either dorsally or laterally Type IV - cervicomedullary tumor	CT and MRI

CT = computed tomography; MRI = magnetic resonance imaging

the tumor. MRI assists in delineating the rostral and caudal pole of these tumors, as well as identifying any associated syrinx or cysts.

The majority of these tumors are benign low grade astrocytomas, and they demonstrate distinct growth patterns (28, 36). These tumors have

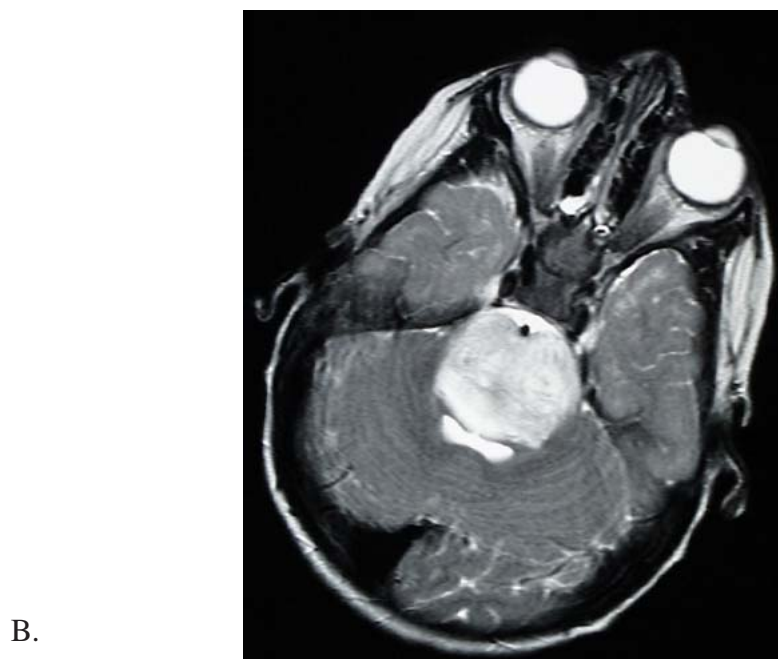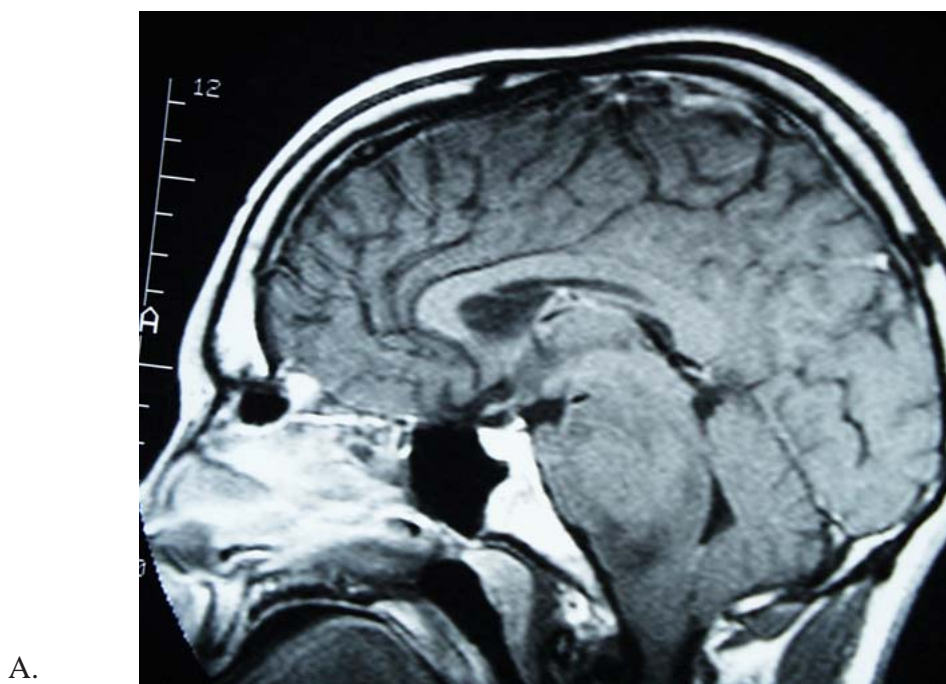
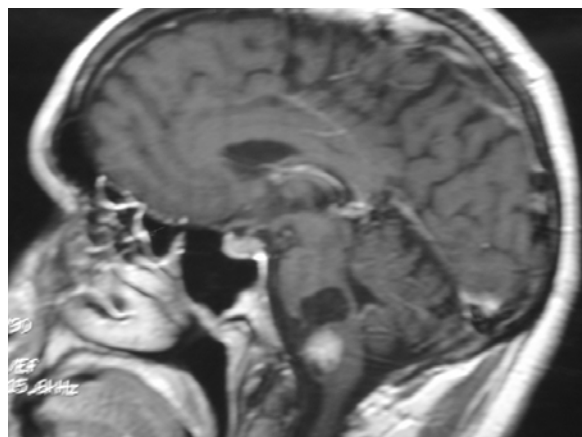
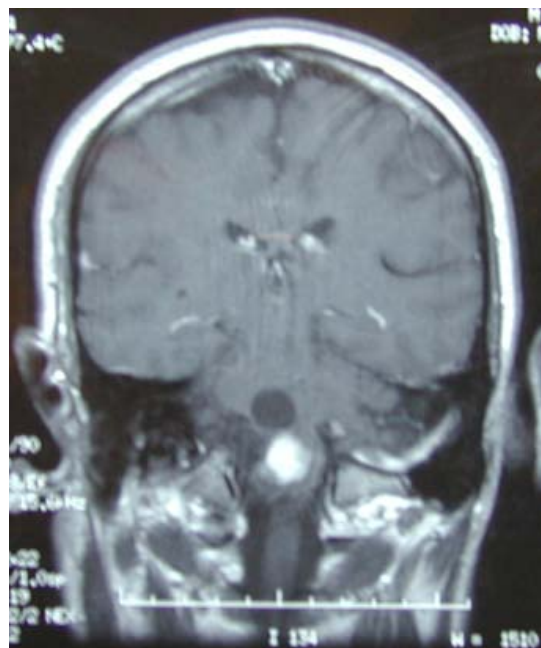


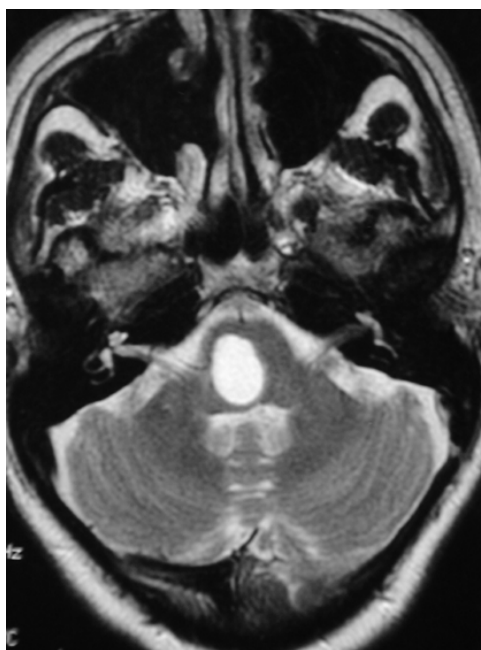
FIGURE 1: Diffuse pontine glioma. (A) Sagittal T1-weighted MRI scan with gadolinium demonstrates an enlarged pons with minimal enhancement. (B) Axial T2-weighted sequence demonstrates the hyperintense signal within the enlarged pons.



A.



B.



C.

FIGURE 2: Focal tumor. (A) Sagittal T1-weighted MRI with gadolinium demonstrates a heterogeneously enhancing tumor within the medulla. (B) Coronal image demonstrates the location within the medulla. (C) Axial T2-weighted MRI demonstrates the intrinsic medullary location.

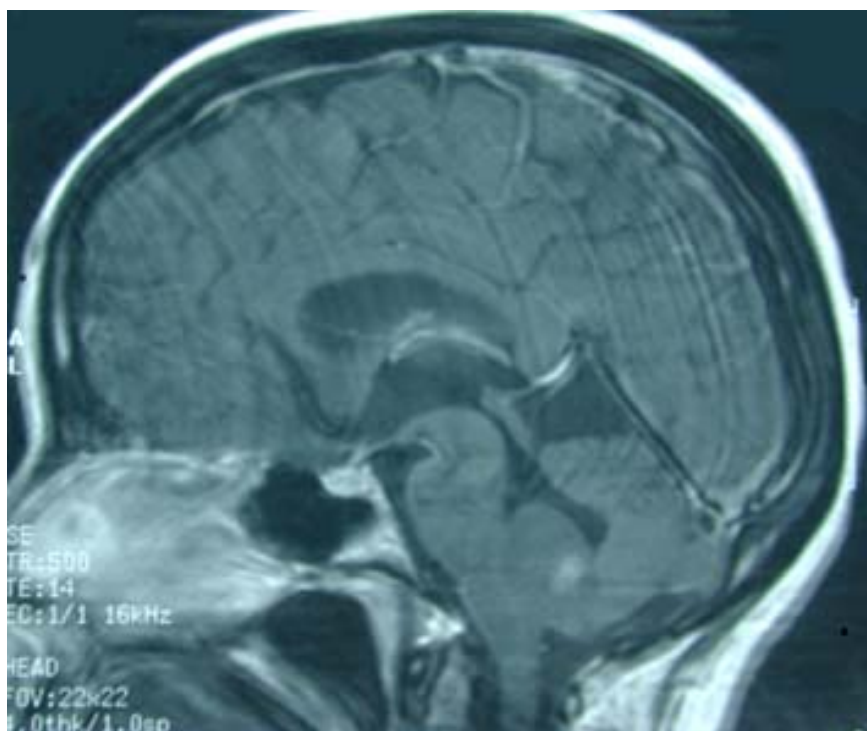


FIGURE 3: Dorsal exophytic glioma. T1-weighted sagittal MRI of an exophytic tumor within the fourth ventricle.

almost no infiltrative capacity and as a consequence their growth is limited rostrally by the decussating white matter tracts of the corticospinal tract and medial lemniscus which act as a barrier for further rostral growth. Tumors which arise within the medulla are confined by the decussating fibers and expand within the medulla, pushing the motor tracts and nuclei peripherally. Only high grade tumors with an infiltrative capacity grow rostrally into the brainstem. As a result, these low grade tumors may appear exophytic and displace the medulla rostrally, while the upper cervical cord appears expanded.

DIAGNOSIS AND MANAGEMENT

The clinical history and presentation are important in the establishment of the tumor histology and overall prognosis. A careful history is obtained from both the child and parents. This is important since, often subtle changes may go unreported if both individuals are not interviewed. For example, old pictures may be necessary to date the onset of cranial neuropathies. Declining school performance, especially related to visual disturbances or symptoms of hydrocephalus, may be the only presenting signs. A detailed history should include previous upper

respiratory tract infections, pneumonia, or changes in voice (3). The time to diagnosis (or length of prodrome) is an indication of the tumor histology.

Malignant lesions invariably have a rapidly progressive course. Children with diffuse brainstem gliomas will often present acutely with multiple cranial nerve signs, ataxia, long tract signs, and cerebellar signs. Diffuse gliomas are unfortunately the most common brainstem lesion, and regrettably, this tumor portends the worst prognosis among the brainstem gliomas. Most children die within 18 months from diagnosis, similar to the clinical course for glioblastoma multiforme (6, 43). There is no role for radical surgery or biopsy since stereotactic biopsy does not change the management strategy (7). A biopsy should be reserved for indeterminate lesions on MRI accompanied with an unusual presentation or when mandated by a study protocol. Diffuse brainstem tumors, which are associated with neurofibromatosis need further investigation, because they tend to have a more favorable prognosis. These NF-1 brainstem tumors typically have an indolent course, reminiscent of their astrocytic counterparts in the hypothalamic/optic chiasm region (46, 51). Care-

ful clinical examination for the stigmata of neurofibromatosis and family history should help in the identification of these lesions. Magnetic resonance spectroscopy has also been shown to be useful in distinguishing diffuse lesions in NF-1 patients (19). Radiation and/or chemotherapy are the current mainstay of treatment for diffuse brainstem gliomas (9).

In contrast, focal tumors are generally low-grade gliomas, and have a longer prodrome (months to years) before diagnosis when compared to the shorter period (weeks to months) for diffuse gliomas. The location of the focal tumor along the brainstem axis influences the clinical presentation. In general, upper brainstem tumors tend to present with hydrocephalus, oculomotor dysfunction and/or cerebellar findings, whereas lower brainstem tumors present with lower cranial nerve deficits and long tract findings.

Midbrain gliomas of the tectum behave as very low-grade lesions (16). Focal tumors of the tectum (tectal gliomas) begin to cause signifi-

cant neurological symptoms when they enlarge and compress the aqueduct of Sylvius thereby producing obstructive hydrocephalus. Tegmental tumors can present with hydrocephalus and oculomotor paresis with or without associated long-tract findings. Focal pontine gliomas generally have a poorer prognosis while focal tumors of the medulla are intermediate. Pontine lesions cause facial paresis, hearing loss or long-tract findings. Concern should be raised when a child presents with a localized focal non-enhancing tumor with rapid progression in symptoms. Atypical tumors which present at a very young age and with leptomeningeal dissemination may represent primitive neuroectodermal tumor (PNET) (63). An excision biopsy should be considered in this situation since treatment protocols for PNETs differ from those for brainstem gliomas.

Tumors of the medulla present with lower cranial nerve deficits, which manifest as changes in voice, swallowing difficulty or pneumonia due to micro-aspirations. Although these focal

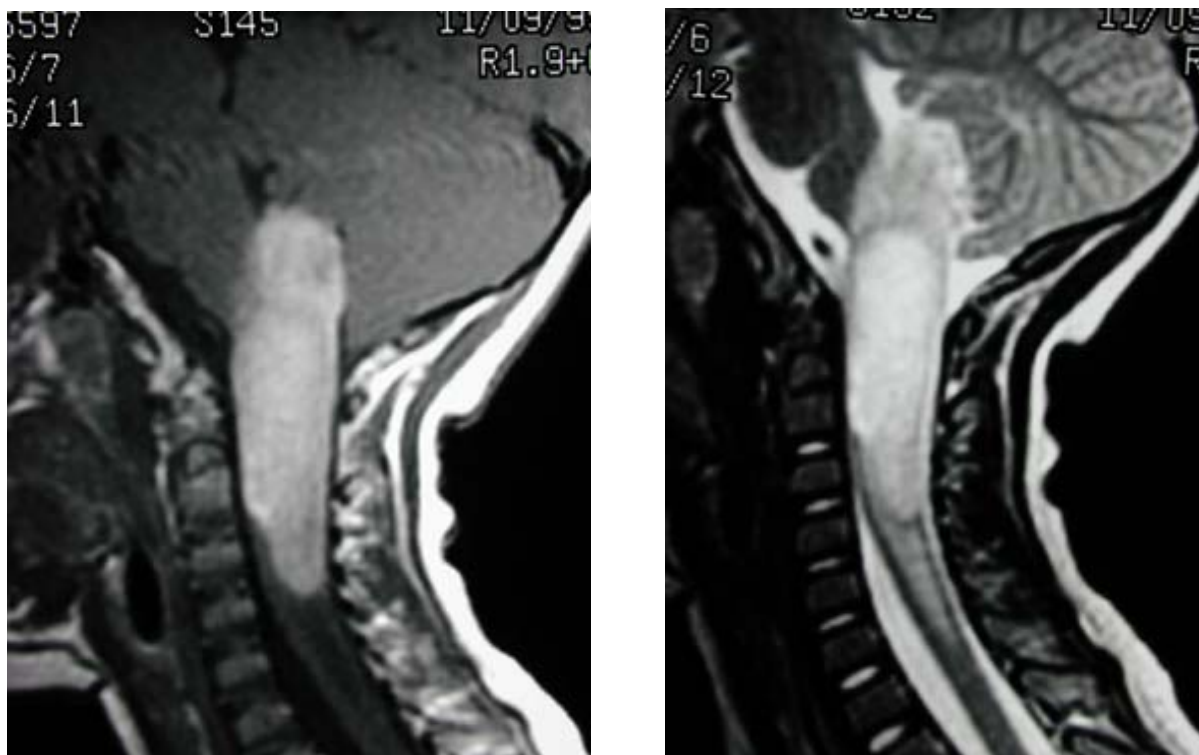

FIGURE 4: Cervicomedullary glioma. (A) Sagittal T1-weighted MRI scan demonstrates the extent of a typical cervicomedullary tumor. (B) Sagittal T2-weighted MRI confirms the extent of tumor

lesions are not infiltrative, they can carry a high surgical morbidity (4). Preoperative medullary dysfunction warns of postoperative complications specifically in patients demonstrating frequent preoperative upper respiratory tract infections, preoperative pneumonia or alteration in voice (3).

Dorsally exophytic tumors may be regarded as a type of focal tumor. There is usually a protracted yet progressive clinical course with symptoms due to either direct compression of the underlying brainstem or to raised intracranial pressure from obstruction of CSF pathways. Young children may present with failure to thrive due to intractable vomiting. Older children may exhibit headache and ataxia. Papilledema and torticollis are common presenting signs, resulting from increased intracranial pressure and chronic tonsillar herniation. The majority of dorsally exophytic tumors can be managed successfully with subtotal resection, and if necessary, CSF diversion (Table 2) (49).

Cervicomedullary brainstem gliomas are also associated with an indolent course. The presentation of these tumors is dependent on the epicenter of the lesion. Two presenting syndromes, a medullary and cervical cord syndrome, have been described. Medullary dysfunction may manifest as failure to thrive due to nausea, vomiting, or dysphagia, upper respiratory tract infection, dysarthria, and sleep apnea. The cervical cord dysfunction will manifest as chronic neck pain and progressive cervical myelopathy with weakness and spasticity. Good long-term outcomes have been achieved with radical resection (Table 3) (12, 26, 53, 61).

OUR SERIES OF BRAINSTEM TUMORS

We retrospectively reviewed our tumor database from 1996 to 2001 for brainstem tumors treated at our center. We treated 135 children with brainstem tumors. There were 85 benign (tectal, focal, dorsal exophytic, and/or cervicomedullary tumors) and 50 malignant tumors. The malignant tumors included 41 diffuse pontine gliomas and 9 tumors which had an equivocal diagnosis on imaging studies. These 9 patients underwent suboccipital craniotomies for radical removal of the tumor. The histology of these children is listed in Table 4. The overall mean survival for this

group of children with diffuse tumors was 12.1 months. This is comparable to previous reports concerning diffuse gliomas treated with various radiotherapy and chemotherapy protocols.

The benign tumors were distributed throughout the brainstem, but the majority of tumors were located in the medulla (Table 5). There were 20 children with tectal gliomas who were treated with endoscopic third ventriculostomy. The remaining patients underwent surgery for radical removal of their tumor. The predominant histology in this group was low-grade astrocytoma or ganglioglioma which accounted for 54%. A malignant, anaplastic astrocytoma or glioblastoma, histology was found in only 12% of cases.

SURGICAL TREATMENT

Careful patient selection is one of the underlying principles behind successful brainstem tumor surgery. The categorization of brainstem tumors has helped to predict growth patterns and identify surgically treatable lesions. Surgery for diffuse brainstem gliomas is generally not indicated. This section will address open surgical treatment of focal, dorsally exophytic and cervicomedullary tumors. Certain focal lesions, particularly tectal gliomas, have an indolent natural history, and do not generally require open surgical management. Tectal gliomas are managed by treatment of symptomatic obstructive hydrocephalus using endoscopic third ventriculostomy or shunting. The advantages of endoscopic third ventriculostomy include avoidance of an implant device and potential for a minimally invasive biopsy of the tumor mass.

General considerations

We have favored early surgery as a first line intervention, particularly before significant progression of symptoms and before other treatments such as radiotherapy or chemotherapy are administered. The goal of surgery is to decrease the tumor burden without incurring significant neurological complications; this goal can often be accomplished without gross total resection, however there is significant risk of morbidity.

Intraoperative neurophysiological mapping and monitoring is recommended for all brainstem cases (24, 47). While MRI may pro-

TABLE 2
Summary of Reported Dorsal Exophytic Brainstem Tumors

Author	Patients	Histology	Surgery	Adjuvant Therapy	Outcome	Progression
Pollack, 1993	18	16 LGA Grade I or II 1 Astrocytoma Grade III 1 Ganglioglioma	Near total	2 patients	17 alive (median, 113 months)	4 patients
Khatib, 1994	12	11 JPA 1 LGA	6 near total 6 subtotal	2	11 alive (median, 26 months)	3
Fischbein, 1996	10	N/A	N/A	N/A	7 alive (mean, 35 months)	N/A

TABLE 3
Summary of Reported Cervicomedullary Tumors

Author	Patients	Histology	Surgery	Adjuvant Therapy	Outcome	Progression
Epstein, 1987	20	11 LGA Grade I or II 4 astrocytoma Grade III 3 ganglioglioma 2 ependymoma	N/A	4 patients	16 alive (median, 24 months)	4/4 of high grade tumors 1/16 of low grade tumors
Robertson, 1994	17	10 LGA 6 ganglioglioma 1 mixed astrocytoma	15 subtotal	2	15 alive (median, 48 months)	1/16 of low grade tumors
Robertson, 1994	4	3 JPA 1 ependymoma	N/A	N/A	N/A	6 patients
Weiner, 1997	39	15 LGA 9 ependymoma 7 ganglioglioma 3 JPA 3 anaplastic astrocytoma 2 mixed glioma	12 gross total 7 near total 15 subtotal 5 partial	none	39 alive (mean, 48 months)	3/4 of high grade tumors 12/35 of low grade tumors

Near total >90% resection, subtotal >50% but <90%, partial <50%.
LGA, low grade astrocytoma; JPA, juvenile pilocytic astrocytoma

TABLE 4

Malignant Tumors of the Brainstem Treated at Beth Israel Medical Center 1996-2001 (Including diffuse pontine gliomas)

Pons	
Diffuse Pontine Glioma	41
Glioblastoma	4
Anaplastic Astrocytoma	2
PNET	1
Medulla	
Anaplastic Ependymoma	1
Anaplastic Astrocytoma	1

TABLE 5

Low Grade Tumors of the Brainstem Treated at Beth Israel Medical Center 1996-2001

Midbrain	
Tectal	20
Focal	16
Pons (focal)	7
Medulla	
Focal	14
Dorsal exophytic	12
Cervicomedullary	16

vide accurate localization of the tumor, it does not provide information regarding the function of surrounding normal tissues. Although safe entry zones (suprafacial /infracial triangles, intercollicular midline incision) have been described, intrinsic tumors of the brainstem often distort the normal anatomy, and thus obscuring normal landmarks (47). Neurophysiological mapping overcomes this limitation by identifying displaced structures, and thus avoiding brainstem injury. In addition, continuous monitoring of standard evoked potentials (motor and sensory), and cranial nerve reflex circuits can be used to give real time feedback as to the integrity of the brainstem during tumor resection (24).

Special microsurgical equipment, which have greatly enhanced the operative technique, include the operating microscope, plated bayonets forceps (29), Nd:YAG contact laser (38), and the Cavitron ultrasonic aspirator (CUSA) (22, 37). The current CUSA models are equipped with smaller handsets that allow them to be safely used in the confined limits of brainstem. The contact Nd:YAG laser provides precision cutting coupled with coagulation of adjacent tissues due to the laser's affinity for hemoglobin. It can be used for tumor resection with minimal injury to the surrounding brainstem cranial nerve nuclei. Surgical approaches to the brainstem are predominantly through the posterior fossa. The prone position provides excellent exposure of the entire brainstem except for upper midbrain tumors. Some surgeons prefer the sitting position (18), however the prone position reduces the risk of venous air embolism and pneumocephalus. In addition, the prone position provides a surgical field that is readily accessible to both the surgeon and assistant. The surgeon's arms are not elevated throughout the case and there is less general fatigue. Proper positioning, especially with regard to neck flexion and shoulder placement is important for adequate visualization of the anticipated lesion. There are many different skull base approaches available depending on the location of the tumor.

Midbrain

Although most tumors of the upper midbrain are managed conservatively with CSF diversion, some tumors in this area progress and require

open surgery. The dorsal midbrain can be exposed by the infratentorial-supracerebellar approach first described by Krause and then popularized by Stein (56). A craniotomy is fashioned to incorporate the transverse sinus. The cerebellum and vermis may then be retracted caudally to expose the dorsal aspect of the mesencephalon. This approach allows direct access to the midbrain without intervening brain tissue (11). The deep venous drainage system, including the vein of Galen and internal cerebral veins, are generally above the surgical field and thus easily avoided. Lesions on the ventral medial aspect of the midbrain near the interpeduncular cistern are reached by a standard pterional approach. Ventral lateral masses of the midbrain may be reached by a subtemporal approach and usually involve splitting the tentorial incisura. It should be kept in mind, however, that the subtemporal approach has the disadvantage of potentially requiring prolonged retraction of the temporal lobe.

Pons

For dorsally-situated tumors of the pons or medulla, a midline suboccipital craniotomy is the most common approach in our practice. A craniotomy is generally preferred over a craniectomy especially in children (34). Replacement of the bone flap provides additional protection, and allows better restoration of anatomical tissue planes, which becomes important in the unfortunate patients who may require multiple resections (42). The telovelar approach provides adequate exposure to all dorsally exophytic tumors (52). Excessive traction on the cerebellar hemispheres and dissection on the vermis should be avoided, because of the risk of cerebellar mutism and pseudobulbar symptoms (50, 62). For focal intrinsic tumors, the resection begins after the floor of the fourth ventricle has been identified and mapped for safe points of entry. If distortion and discoloration of the floor are insufficient to localize the tumor, ultrasound can be used to determine where the tumor is closest to the floor.

Tumors of the ventral lateral aspect of the pons extending into the cerebellopontine angle may be reached with the lateral retrosigmoid approach. The asterion, which is formed by the lambdoid and temporal squamous sutures, is a

useful landmark for planning the bony removal. The junction of the transverse and sigmoid sinuses is identified, and used as a guide for dural opening. The tumor may be debulked with special attention to the location of the tracts of cranial nerves 5, 7 and 8, and, if involving the medulla, 9 and 10.

Medulla and upper cervical spine

For intrinsic tumors of the medulla, a suboccipital craniotomy with removal of the dorsal lateral bony rim of the foramen magnum enhances the exposure of the bulging medulla. A cervical laminotomy or laminectomy is performed for tumors which extend caudally into the cervical region. The medulla is typically displaced superiorly as the tumor grows posterior to the obex. The tumor is quite superficial here, almost invariably subpial in location. The posterior inferior cerebellar arteries, which may be displaced, must be preserved to avoid cerebellar or brainstem infarcts. However, superficial pial vessels may be taken if obstructing the intramedullary component of tumor.

Special considerations

One of the early considerations for a brainstem focal tumor is to determine a safe entry point. Cystic focal tumors are generally easier to treat than solid lesions, because they can be more easily entered and their walls inspected for tumor nodules without having to manipulate the surrounding tissue. Discoloration and loss of surface markings may be used as rough guides in mapping the floor of the fourth ventricle when searching for safe entry zones. The contact laser is used to perform the initial incision or myelotomy into the brainstem. This process eliminates the superficial feeding blood vessels and initiates tumor retraction. What often hinders complete resection is the lack of tumor demarcation from the surrounding brain. The neurosurgeon must remember that complete resection is prohibitive if there is no discernible plane between tumor and brainstem parenchyma due to the high probability for postoperative morbidity. It should also be kept in mind that a near-total resection, with a thin residual tumor margin, is equally successful. It is important to minimize retraction of surrounding neural tissue dur-

ing the resection. The tumor is removed in a piecemeal fashion using a combination of suction-aspiration and the CUSA. Tumor debulking and dissection is achieved by working from the inside-out direction. The Nd:YAG laser is sometimes helpful in removing small amounts of tumor at the margins or in tight confines. Cautery is to be avoided at the margins of the tumor as this will frequently result in injury to the surrounding functional tissue. Mapping of the walls of the resection cavity can be performed in an attempt to define tumor margins. Tissue specimens are always sent early for frozen section analysis. If the lesion is identified as a high-grade tumor, then the operation is generally curtailed, because there has been no proven long-term benefit to surgical debulking of these aggressive lesions.

Dorsally exophytic tumors were the first type of brainstem gliomas to be routinely treated with radical surgery (30, 41, 49). Most of the dissection and removal is accomplished outside of the brainstem since these tumors are predominantly localized in the fourth ventricle. These tumors are approached via a standard midline suboccipital approach. One of the most important aspects of the case is to progressively debulk the tumor while keeping the floor of the fourth ventricle in view as it is important not to enter the brainstem parenchyma. Cranial nerves 6 & 7 are especially susceptible to injury because their nuclei and/or tracks are close to the dorsal surface of the stem and the floor of the 4th ventricle. The area immediate around the obex and calamus scriptorius should be avoided, because of possible injury to cranial nuclei for 10 & 12. When these structures are injured, patients develop impaired swallowing, loss of cough reflex, and dysphonia. A subtotal resection with preservation of neurological function is the goal of the surgery.

Patients with cervicomedullary tumors also benefit from radical surgical treatment (12, 26, 53, 61). A midline suboccipital craniotomy and cervical laminectomies provide the necessary exposures. Excessive removal of cervical lamina is avoided to prevent the development of spinal deformity. Osteoplastic laminectomy is considered if a multilevel cervical laminectomy is required (2). Although this technique may not al-

ways prevent deformity, there is re-ossification of the bony segments which can avoid the cosmetic deformity frequently seen with multilevel laminectomies. The location of the tumor and any associated cysts is confirmed with the ultrasound. A midline myelotomy is performed with the Nd:YAG laser in order to avoid injury to the posterior columns. The myelotomy is first directed over any associated rostral or caudal cyst, and then extended over the solid part of the tumor. Identification of the dorsal root entry zones bilaterally is necessary to properly find the midline. This can be done visually or with mapping of the dorsal surface to establish the midline between the two dorsal columns (24). The tumor's dorsal surface is exposed, and the tumor entered with a piecemeal removal from the center outwards performed. This is done using the CUSA, laser, and bipolar cautery with the same techniques described earlier for intrinsic focal brainstem tumors. Meticulous care in the closure is important for the avoidance of a CSF leak, a complication not uncommon when operating on these tumors.

Potential complications

Clinically, the patient's preoperative symptoms may be transiently or permanently worsened after surgery. For that reason special care needs to be taken during the postoperative period (60).

If a significant amount of the medulla is involved with tumor, the patient is left intubated for at least 48 to 72 hours after surgery. This is critically important for any patient with evidence of dysfunction in lower cranial nerves. Impaired central respiratory function may result in carbon dioxide retention and progressive hypoxia leading to respiratory arrest and further neurological injury which is usually permanent (4). The patient is weaned from the ventilator after 24 consecutive hours of stable respiratory drive.

Cranial nerve deficits are variable and dependent on the surgical approach. Surgery within the pons can result in transient diplopia due to internuclear ophthalmoplegia. This complication is often transient and improves. For persistent diplopia, ophthalmologic treatment with special eyeglass prisms may be necessary. Facial palsy can be devastating not only cosmetically but also

functionally with regard to corneal injury. Several plastic surgical procedures have been developed to restore facial tone and protect the eye from corneal abrasions and keratitis (54). Damage to the lower cranial nerves (9-12) can result in severe dysphagia, vocal cord paralysis, and loss of gag and cough reflexes. As a result, these patients are at risk for subclinical micro-aspirations, which may lead to recurrent and debilitating pneumonia. Formal swallowing evaluations are performed for all patients with questionable function before advancement of diet. Because of these latter risks we have learned to be aggressive in employing tracheostomy and feeding gastrostomy in the first several months after surgery when there is swallowing dysfunction.

ONCOLOGIC OUTCOME

Although a neuro-oncologist coordinates the adjuvant care for all patients, the neurosurgeon should be aware of the protocols for brainstem gliomas. Radiation therapy has provided only marginal gains in the overall prognosis for diffuse high-grade tumors. Standard irradiation treatment combined with new chemotherapy protocols have had some mixed results (Table 6) (15, 20, 31, 32, 39, 40, 59). These issues are reviewed elsewhere (9). There are new therapeutic options under current investigation including convection-enhanced delivery (44, 55), radio-sensitizing agents, hyperbaric and interstitial radiotherapy.

There have been minimal improvements in long-term survival of low grade brainstem gliomas directly attributed to adjuvant therapy. Given the significant advances in surgical management of brainstem lesions and decrease in surgical morbidity, second surgery has become a viable option (17). Indications for the second surgery have included: (1) delayed, recurrent growth in either the solid or cystic component of the tumor resulting in new symptoms or (2) re-exploration after the initial resection was halted prematurely due to transient intraoperative injury confirmed by monitoring. The goal of these re-operations is identical to that of the first operation; i.e., sufficient debulking of the tumor so as to lessen symptoms without causing progression in neurologic deficits.

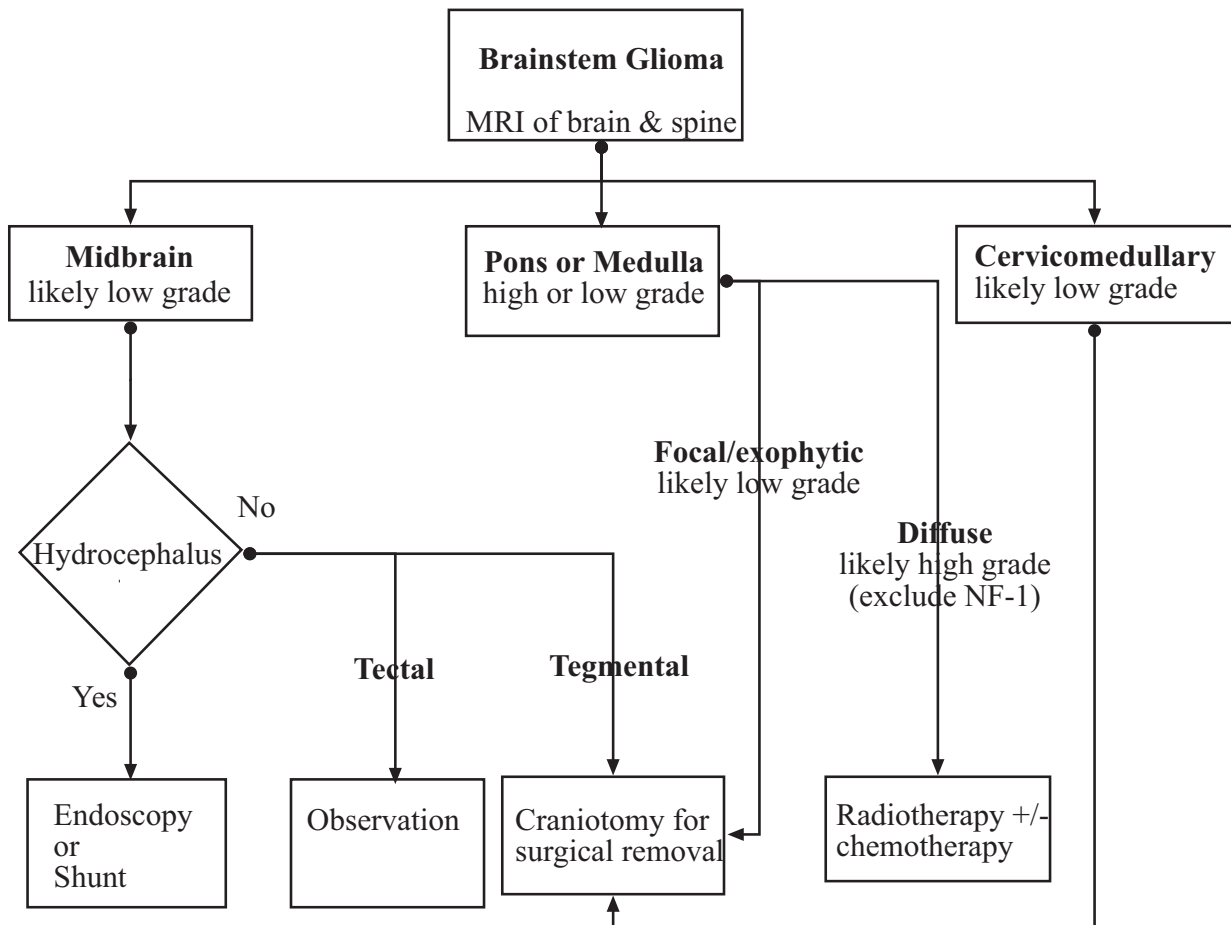


FIGURE 5. Surgical management algorithm for brainstem tumors in children
NF-1 = neurofibromatosis 1

TABLE 6

Chemotherapy and Radiotherapy Protocols for the Treatment of Diffuse Pontine Gliomas

Chemotherapy	Radiotherapy	Patients	Outcome
5-FU, CCNU, HDU, Misonidazole	55 Gy	28	MST 44 weeks
COPP	56 Gy	7	Progression at 4 months
VCR, CCNU, Prednisone	50-60 Gy	35 RT 39 RT + Chemo	MST 9 months both arms
VP-16, Trofosfamide	54 Gy	18	PFS 179 days
Carboplatin, VP-16	70.2 Gy	9	8/9 died at 44 weeks

MST, mean survival time; PFS, progression-free survival

CONCLUSION

Brainstem gliomas are a heterogeneous group of tumors, which may be diffuse, focal, dorsally exophytic, or cervicomedullary. These classification schemes help in predicting growth pat-

terns and identifying surgically treatable lesions. Almost all diffuse tumors are malignant and non-resectable. The majority of other tumors are focal low-grade astrocytomas that are amenable to surgical cure and long-term survival.

REFERENCES

- Abbott R: Tumors of the medulla. **Neurosurg Clin N Am** 4:519-527, 1993.
- Abbott R, Feldstein N, Wisoff JH, Epstein FJ: Osteoplastic laminotomy in children. **Pediatr Neurosurg** 18:153-156, 1992.
- Abbott R, Shiminski-Maher T, Epstein FJ: Intrinsic tumors of the medulla: predicting outcome after surgery. **Pediatr Neurosurg** 25:41-44, 1996.
- Abbott R, Shiminski-Maher T, Wisoff JH, Epstein FJ: Intrinsic tumors of the medulla: surgical complications. **Pediatr Neurosurg** 17:239-244, 1991.
- Albright AL: Brain stem gliomas, in Youmans J 4th (ed) *Neurological Surgery*. Philadelphia, W.B. Saunders Co., 1996, pp 2603-2611.
- Albright AL, Guthkelch AN, Packer RJ, Price RA, Rourke LB: Prognostic factors in pediatric brainstem gliomas. **J Neurosurg** 65:751-755, 1986.
- Albright AL, Packer RJ, Zimmerman R, Rorke LB, Boyett J, Hammond GD: Magnetic resonance scans should replace biopsies for the diagnosis of diffuse brain stem gliomas: a report from the Children's Cancer Group. **Neurosurgery** 33:1026-1030, 1993.
- Allen J: Brain stem glioma. **Neurology and Neurosurgery: Update Series** 4:2-7, 1983.
- Allen JC, Siffert J: Contemporary chemotherapy issues for children with brainstem gliomas. **Pediatr Neurosurg** 24:98-102, 1996.
- Alvisi C, Cerisoli M, Maccheroni ME: Long-term results of surgically treated brainstem gliomas. **Acta Neurochir** 76:12-17, 1985.
- Ammirati M, Bernardo A, Musumeci A, Bricolo A: Comparison of different infratentorial-supracerebellar approaches to the posterior and middle incisural space: a cadaveric study. **J Neurosurg** 97:922-928, 2002.
- Behnke J, Christen HJ, Bruck W, Markakis E: Intra-axial endophytic tumors in the pons and/or medulla oblongata. I. Symptoms, neuroradiological findings, and histopathology in 30 children. **Childs Nerv Syst** 13:122-134, 1997.
- Beltramello A, Lombardo MC, Masotto B, Bricolo A: Imaging of brain stem tumors. **Operative Techniques in Neurosurgery** 3:87-105, 2000.
- Berger MS, Edwards MS, LaMasters D, Davis RL, Wilson CB: Pediatric brain stem tumors: radiographic, pathological, and clinical correlations. **Neurosurgery** 12:298-302, 1983.
- Blaney S, Berg SL, Pratt C, Weitman S, Sullivan J, Luchtman-Jones L, Bernstein M: A phase I study of irinotecan in pediatric patients: a pediatric oncology group study. **Clin Cancer Res** 7:32-37, 2001.
- Bowers DC, Georgiades C, Aronson LJ, Carson BS, Weingart JD, Wharam MD, Melhem ER, Burger PC, Cohen KJ: Tectal gliomas: natural history of an indolent lesion in pediatric patients. **Pediatr Neurosurg** 32:24-29, 2000.
- Bowers DC, Krause TP, Aronson LJ, Barzi A, Burger PC, Carson BS, Weingart JD, Wharam MD, Melhem ER, Cohen KJ: Second surgery for recurrent pilocytic astrocytoma in children. **Pediatr Neurosurg** 34:229-234, 2001.
- Bricolo A: Surgical management of intrinsic brain stem gliomas. **Operative Techniques in Neurosurgery** 3:137-154, 2000.
- Broniscer A, Gajjar A, Bhargava R, Langston JW, Heideman R, Jones D, Kun LE, Taylor J: Brain stem involvement in children with neurofibromatosis type 1: role of magnetic resonance imaging and spectroscopy in the distinction from diffuse pontine glioma. **Neurosurgery** 40:331-338, 1997.
- Broniscer A, Leite CC, Lanchote VL, Machado TM, Cristofani LM: Radiation therapy and high-dose tamoxifen in the treatment of patients with diffuse brainstem gliomas: results of a Brazilian cooperative study. Brainstem Glioma Cooperative Group. **J Clin Oncol** 18:1246-1253, 2000.

21. Choux M, Lena G, Do L: Brainstem tumors, in Choux M, Di Rocco C, Hockley A (eds): **Pediatric Neurosurgery**. New York: Churchill Livingstone, 2000, pp 471-491.
22. Constantini S, Epstein F: Ultrasonic dissection in neurosurgery, in Wilkins RH, Rengachary SS (eds): **Neurosurgery**, ed 2, New York: McGraw-Hill, 1996, Vol 1, pp 607-608.
23. Dechambre S, Duprez T, Lecouvet F, Raftopoulos C, Gosnard G: Diffusion-weighted MRI postoperative assessment of an epidermoid tumour in the cerebellopontine angle. **Neuroradiology** 41:829-831, 1999.
24. Deletis V, Sala F, Morota N: Intraoperative neurophysiological monitoring and mapping during brain stem surgery: a modern approach. **Operative Techniques in Neurosurgery** 3:109-113, 2000.
25. Epstein F, McCleary EL: Intrinsic brain-stem tumors of childhood: surgical indications. **J Neurosurg** 64:11-15, 1986.
26. Epstein F, Wisoff J: Intra-axial tumors of the cervicomedullary junction. **J Neurosurg** 67:483-487, 1987.
27. Epstein F, Wisoff JH: Intrinsic brainstem tumors in childhood: surgical indications. **J Neurooncol** 6:309-317, 1988.
28. Epstein FJ, Farmer JP: Brain-stem glioma growth patterns. **J Neurosurg** 78:408-412., 1993.
29. Epstein FJ, Ozek M: The plated bayonet: a new instrument to facilitate surgery for intra-axial neoplasms of the spinal cord and brain stem. Technical note. **J Neurosurg** 78:505-507, 1993.
30. Fischbein NJ, Prados MD, Wara W, Russo C, Edwards MS, Barkovich AJ: Radiologic classification of brain stem tumors: correlation of magnetic resonance imaging appearance with clinical outcome. **Pediatr Neurosurg** 24:9-23, 1996.
31. Freeman CR, Bourgouin PM, Sanford RA, Cohen ME, Friedman HS, Kun LE: Long term survivors of childhood brain stem gliomas treated with hyperfractionated radiotherapy. Clinical characteristics and treatment related toxicities. The Pediatric Oncology Group. **Cancer** 77:555-562, 1996.
32. Freeman CR, Kepner J, Kun LE, Sanford RA, Kadota R, Mandell L, Friedman H: A detrimental effect of a combined chemotherapy-radiotherapy approach in children with diffuse intrinsic brain stem gliomas? **Int J Radiat Oncol Biol Phys** 47:561-564, 2000.
33. Gilday DL, Ash J: Accuracy of brain scanning in pediatric craniocerebral neoplasms. **Radiology** 117:93-97, 1975.
34. Gnanalingham KK, Lafuente J, Thompson D, Harkness W, Hayward R: Surgical procedures for posterior fossa tumors in children: does craniotomy lead to fewer complications than craniectomy? **J Neurosurg** 97:821-826, 2002.
35. Hoffman HJ, Becker L, Craven MA: A clinically and pathologically distinct group of benign brain stem gliomas. **Neurosurgery** 7:243-248, 1980.
36. Jallo G, Kothbauer K, Epstein F: Surgical management of cervicomedullary and dorsally exophytic brain stem tumors. **Operative Techniques in Neurosurgery** 3:131-136, 2000.
37. Jallo GI: CUSA EXcel ultrasonic aspiration system. **Neurosurgery** 48:695-697, 2001.
38. Jallo GI, Kothbauer KF, Epstein FJ: Contact laser microsurgery. **Childs Nerv Syst** 18:333-336, 2002.
39. Kaplan AM, Albright AL, Zimmerman RA, Rorke LB, Li H, Boyett JM, Finlay JL, Wara WM, Packer RJ: Brainstem gliomas in children. A Children's Cancer Group review of 119 cases. **Pediatr Neurosurg** 24:185-192, 1996.
40. Kedar A, Maria BL, Graham-Pole J, Ringdahl DM, Quisling RG, Mickle JP, Mendenhall NP, Marcus RB, Jr., Gross S: High-dose chemotherapy with marrow reinfusion and hyperfractionated irradiation for children with high-risk brain tumors. **Med Pediatr Oncol** 23:428-436, 1994.
41. Khatib ZA, Heideman RL, Kovnar EH, Langston JA, Sanford RA, Douglas EC, Ochs J, Jenkins JJ, Fairclough DL, Greenwald C, et al.: Predominance of pilocytic histology in dorsally exophytic brain stem tumors. **Pediatr Neurosurg** 20:2-10, 1994.
42. Kurpad SN, Cohen AR: Posterior fossa craniotomy: an alternative to craniectomy. **Pediatr Neurosurg** 31:54-57, 1999.
43. Littman P, Jarrett P, Bilaniuk LT, Rorke LB, Zimmerman RA, Bruce DA, Carabell SC, Schut L: Pediatric brain stem gliomas. **Cancer** 45:2787-2792, 1980.

44. Lonser RR, Walbridge S, Garmestani K, Butman JA, Walters HA, Vortmeyer AO, Morrison PF, Brechbiel MW, Oldfield EH: Successful and safe perfusion of the primate brainstem: in vivo magnetic resonance imaging of macromolecular distribution during infusion. **J Neurosurg** 97:905-913, 2002.
45. Matson DD: Tumors of the posterior fossa. In: *Neurosurgery of Infancy and Childhood*. 2nd (ed) Springfield, IL, Thomas, 1969, pp 469-477.
46. Milstein JM, Geyer JR, Berger MS, Bleyer WA: Favorable prognosis for brainstem gliomas in neurofibromatosis. **J Neurooncol** 7:367-371, 1989.
47. Morota N, Deletis V, Epstein FJ, Kofler M, Abbott R, Lee M, Ruskin K: Brain stem mapping: neurophysiological localization of motor nuclei on the floor of the fourth ventricle. **Neurosurgery** 37:922-930, 1995.
48. Murakami N, Matsushima T, Kuba H, Ikezaki K, Morioka T, Mihara F, Inamura T, Fukui M: Combining steady-state constructive interference and diffusion-weighted magnetic resonance imaging in the surgical treatment of epidermoid tumors. **Neurosurg Rev** 22:159-162, 1999.
49. Pollack IF, Hoffman HJ, Humphreys RP, Becker L: The long-term outcome after surgical treatment of dorsally exophytic brain-stem gliomas. **J Neurosurg** 78:859-863, 1993.
50. Pollack IF, Polinko P, Albright AL, Towbin R, Fitz C: Mutism and pseudobulbar symptoms after resection of posterior fossa tumors in children: incidence and pathophysiology. **Neurosurgery** 37:885-893, 1995.
51. Raffel C, McComb JG, Bodner S, Gilles FE: Benign brain stem lesions in pediatric patients with neurofibromatosis: case reports. **Neurosurgery** 25:959-964, 1989.
52. Rhoton AL: Cerebellum and Fourth Ventricle. **Neurosurgery(Supplement)** 47:S7-S27, 2000.
53. Robertson PL, Allen JC, Abbott IR, Miller DC, Fidel J, Epstein FJ: Cervicomedullary tumors in children: a distinct subset of brainstem gliomas. **Neurology** 44:1798-1803, 1994.
54. Rose E: *Aesthetic Facial Restoration*. New York: Lippincott-Raven Publishers, 1998.
55. Sandberg DI, Edgar MA, Souweidane MM: Convection-enhanced delivery into the rat brainstem. **J Neurosurg** 96:885-891, 2002.
56. Stein B: The infratentorial supracerebellar approach to pineal lesions. **J Neurosurg**:197-202, 1971.
57. Stroink AR, Hoffman HJ, Hendrick EB, Humphreys RP, Davidson G: Transependymal benign dorsally exophytic brain stem gliomas in childhood: diagnosis and treatment recommendations. **Neurosurgery** 20:439-444, 1987.
58. Walker DA, Punt JA, Sokal M: Clinical management of brain stem glioma. **Arch Dis Child** 80:558-564, 1999.
59. Walter AW, Gajjar A, Ochs JS, Langston JW, Sanford RA, Kun LE, Heideman R: Carboplatin and etoposide with hyperfractionated radiotherapy in children with newly diagnosed diffuse pontine gliomas: a phase I/II study. **Med Pediatr Oncol** 30:28-33, 1998.
60. Wang G, Zhang J, Sun M, Wang C: Surgical management of brainstem mass lesions: respiratory insufficiency occurrence and recovery. **Neurosurgery Quarterly** 11:302-313, 2001.
61. Weiner HL, Freed D, Woo HH, Rezai AR, Kim R, Epstein FJ: Intra-axial tumors of the cervicomedullary junction: surgical results and long-term outcome. **Pediatr Neurosurg** 27:12-18, 1997.
62. Wisoff JH, Epstein FJ: Pseudobulbar palsy after posterior fossa operation in children. **Neurosurgery** 15:707-709, 1984.
63. Zagzag D, Miller DC, Knopp E, Farmer JP, Lee M, Biria S, Pellicer A, Epstein FJ, Allen JC: Primitive neuroectodermal tumors of the brainstem: investigation of seven cases. **Pediatrics** 106:1045-1053, 2000.

Correspondence:

Jallo GI, Division of Pediatric Neurosurgery, The Johns Hopkins Hospital, Harvey 811, 600 North Wolfe Street, Baltimore, MD 21287. Tel.: 410-955 7851; Fax.: 410-955 7862; gjallo1@jhmi.edu

Submitted: 20 December 2002

Accepted: 26 May 2003

Published: 21 August 2003

COMMENTS

The authors have provided a useful review article on the current approaches to brainstem gliomas. Based on a five year review of their experience with these lesions they have proposed a surgical algorithm of management. This distinguishes between inoperable tumours and those amenable to surgery. The article provides helpful guidelines to differentiate these tumours based on the clinical history and radiological findings. The related literature review is comprehensive, up-to-date and correlates with the text.

Bruce Mathew

Hull Royal Infirmary
Hull, UK

I read this article with deep interest. There is no new knowledge however, this is an excellent review and retains enough information for the practioners to appreciate.

Diffusely involved tumors in the brainstem are biologically malignant and not amenable to surgical resection. The surgery has no role in the treatment except for CSF diversion surgery for

associated obstructive hydrocephalus. Radiation and chemotherapy are the current mainstay of treatment, however the results of these adjunctive treatment are disappointing, and do not improve the long term prognosis.

Surgery can be of help when the tumor is focal, exophytic or preferably localized in the cervicomedullary junctional area. Although it seems to be that there are some benefits from surgery, yet it poses some concern due to an unacceptable postoperative morbidity and or the risk of the long term neurological deficits.

The statistics show that regardless of different modes of treatment more than 80% of the patients will succumb within 2 years of diagnosis.

Authors illustrated their wide experiences in 135 cases of brain stem tumors. The perioperative consideration and surgical techniques are elegantly described. The authors are to be congratulated for this excellent review article.

Yoon S Hahn

University of Illionois at Chicago
Chicago, US

