

Medulloblastoma : An Overview

*M. Berman, Ph.D.

Integration of Clinical Observations
and Recent Research

*Email: berman.mike@comcast.net

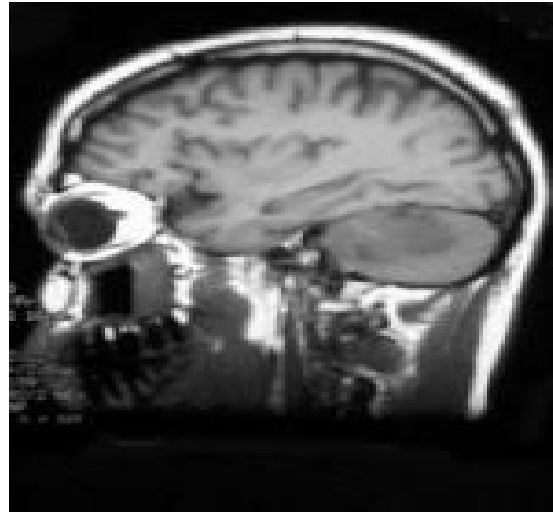Introduction

Medulloblastoma is a highly malignant primary brain tumor that originates in the cerebellum or posterior fossa. Tumors that originate in the cerebellum are referred to as infratentorial because they occur below the tentorium, a thick membrane that separates the cerebral hemispheres of the brain from the cerebellum. Another term for medulloblastoma is infratentorial PNET. Medulloblastoma is the most common PNET originating in the brain.[1] All PNET tumors of the brain are invasive and rapidly growing tumors that, unlike most brain tumors, spread through the cerebrospinal fluid (CSF) and frequently metastasize to different locations in the brain and spine.

Incidence

- Medulloblastoma is a malignant brain tumor, comprising 14.5% of newly diagnosed cases. In adults, Medulloblastoma is rare. The incidence is higher in males(62%) than in females (38%). Medulloblastoma and other PNET tumors are more prevalent in younger children than in older children. 40% of patients are diagnosed before the age of 5, 31% are between the ages of 5 and 9, 18.3% are between the ages of 10 and 14, 12.7% between 15 and 19.

Medulloblastoma in a 27-year-old man



Click to add text

Pathology/Diagnosis

- 1. Distinctive on T1- and T2-weighted MRI, is solid pink-gray and is well-circumscribed on MRI with heterogeneous enhancement.
- 2. Typical location adjacent to and extension into the fourth ventricle.
- 3. Histologically diverse, observed are both perivascular pseudorosettes and Homer-Wright rosette pseudorosettes, the latter characteristic of medulloblastoma; also classic rosettes with tumor cells around a central lumen.
- 4. Correct diagnosis might require ruling out atypical teratoid rhabdoid tumor (ATRT).

More Recent WHO Pathologic Classification

- **1.classic (80%). Small, symmetrical nuclei; cells in layers or sheets.**
- **2.anaplastic- not differentiated.**
- **3. large cell- relatively high ratio of cytoplasm to nucleus;anaplasia.**
- **4.nodular desmoplastic- clusters of cells surrounded by collagen rich tissue;nodules have characteristics of early differentiation based on morphological/molecular features.**
- **5.medulloblastoma with extensive nodularity .**

Risk Stratification Based on:

- 1. age
- 2 metastatic status
- 3 extent of surgical resection
- 4 histological presence or absence of diffuse anaplasia.
- 5 Standard risk patients are over the age of 3 years with localized disease and without anaplastic subtype. All other patients are considered at high risk.

Metastasis Staging

The metastasis stage is derived from the Chang classification staging system. The M stage classification is as follows:

- M0 - No gross subarachnoid or hematogenous metastasis
- M1 - Microscopic tumor cells found in CSF
- M2 - Gross nodular seeding in cerebellum, cerebral subarachnoid space, or in the third or fourth ventricles
- M3 - Gross nodular seeding in spinal subarachnoid space
- M4 - Extraneuraxial metastasis.

Levels of Risk Considered Further

- Average-risk disease: This risk group is defined as patients older than 3 years who are at stage M0 with less than 1.5 cm² of residual tumor postoperatively. The 5-year survival rate for this group is currently more than 80%
- Poor-risk disease: This risk group is defined as patients older than 3 years who are at stage M1-M4 and/or with more than 1.5 cm² of residual tumor postoperatively. The 5-year survival rate for this group is currently 30-60%.
- Infants: This group is defined as patients younger than 3 years. This group has the worst prognosis, regardless of M stage and extent of postoperative residual disease. The 5-year survival rate is approximately 30%; however, patients with metastatic disease do considerably worse. Those infants with desmoplastic tumors are more likely to survive.

Treatment and Prognosis

- Treatment begins with maximal **resection** of the tumor. The addition of radiation to the entire neuraxis and **chemotherapy** may increase the disease-free survival. This combination may permit a 5 year survival in more than 80% of cases. The presence of desmoplastic features such as connective tissue formation offers a better prognosis. Prognosis is worse if the child is less than 3 years old, there is an inadequate degree of resection, or if there is any CSF, spinal, supratentorial or systemic spread. Dementia post radiotherapy and chemotherapy is a common outcome appearing two to four years following treatment.
- Increased intracranial pressure may be controlled with **corticosteroids** or a ventriculoperitoneal **shunt**.

[edit]**Chemotherapy**

- Chemotherapy is now an important part of treatment for all patients with medulloblastoma. It can significantly reduce risk of recurrence (which is typically fatal). There are a couple of different chemotherapeutic regimens for medulloblastoma, but most involve a combination of **lomustine, cisplatin, carboplatin, vincristine** or **cyclophosphamide**. In younger patients (less than 3–4 years of age), chemotherapy can delay, or in some cases possibly even eliminate, the need for radiotherapy. [

Significant Long-term Toxicity

- neurocognitive impairment
- neuropathy, endocrinopathy, impaired bone growth, impaired motor function, hearing loss
- secondary malignancy
- These side-effects are most closely related to dose of radiation therapy
- age at diagnosis
- factors at presentation such as hydrocephalus and shunting

Medulloblastoma: Advances and Challenges

F1000 Biol Reports 2011

[Implications of Subtypes]

- .
- 1. Recently, molecular and genomic studies have shown medulloblastoma to be a heterogeneous disease made up of distinct disease subtypes. The importance of this finding is that response to therapy appears to be subtype-specific.
- 2. Nevertheless, most patients are still treated according to risk stratification methods based on the clinically defined presence or absence of disseminated disease, which take no account of these newly- defined subtypes.
- 3. The potential, however, to vastly reduce therapy-mediated toxicity to patients with tumor subtypes that have good outcomes, while improving therapy through targeting for the poor responders, is now palpable.
- 4. Critical to this effort will be the ongoing refinement of our understanding of medulloblastoma subgroups at the molecular level and the development of mouse models that faithfully recapitulate tumor subtypes

Molecular Analysis-Purpose: To Correlate Prognosis/Mechanisms in Order to Treat Subtypes Effectively



- 1. Karyotyping (Chromosome Structure)
- 2. Whole Genome Sequencing
- 3. Gene Amplification (FISH; Comparative Genomic Hybridization)
- 4. Gene Expression (microarray, RT/PCR)
- 5. Signaling Pathway Activation (SHh, Wnt, Notch, BMP) (Western Blots)
- 6. Gene Sequencing (Mutational Activation of Signaling pathway (Ptch1, SMO)
- 7. Tissue Immunohistochemistry (identify subtype)

Molecular Genetics

- 1. There are both heritable and sporadic forms of medulloblastoma; most (95%) patients present as sporadic cases. Loss of part of chromosome 17, thought to bear a tumor suppressor, is the most common genetic lesion and might contribute due to loss of heterozygosity to large cell/anaplastic forms of the disease.
- **2 Heritable forms** : Li-Fraumeni syndrome results from p53 gene inactivation [or loss of tumor suppressor distal to p53 on chromosome 17] and often presents as medulloblastoma.

Turcot syndrome is a result of APC (adenomatous polyposis coli) gene inactivation [possibly relating to interaction with microtubules].

Naevoid basal cell carcinoma, or Gorlin syndrome, is associated with a mutation in PTCH1 or PTCH2 (the Sonic Hedgehog (SHh) receptor) or suppressor of fused (SUFU). Identification of the gene associated with Gorlin syndrome led to the analysis of sporadic medulloblastoma. It was found that the hedgehog pathway is activated in a variety of sporadic cases, as it is in heritable Gorlin syndrome. (PTCH-1=9q22.3) (SUFU=10q24.32)

A Sampling of Papers Defining Subgroups

- **1. Cho, Y-J et al. Integrative Genomic Analysis of Medulloblastoma Identifies a Molecular Subgroup That Drives Poor Clinical Outcome JCO 29:1424, 2011.**
- **2. Koster, K. et al Integrated genomics identifies five medulloblastoma subtypes with distinct genetic profiles, pathway signatures and clinopathological features PLoS 3: e308820008, 2008.**
- **3. Schwalbe, E. et al. Rapid diagnosis of medulloblastoma molecular subgroups. Clin Cancer Res 17:1883, 2011.**
- **4. Tamayo, P. et al. Predicting Relapse in Patients with Medulloblastoma by Integrating Evidence from Clinical and Genomic Features. JCO 29: 1416, 2011.**
- **5. Clifford, S. et al. Wnt/Wingless pathway activation and chromosome 6 loss characterize a distinct molecular subgroup of medulloblastomas associated with a favorable prognosis. Cell Cycle 5: 2666, , 2006.**
- **6. DeBartoli, M. et al. Medulloblastoma outcome is adversely associated with overexpression of EEF1D, RPL30 and RPS20 on the long arm of chromosome 8. BMC Canc: 6: 223., 2006**

Definition of Disease-Risk Stratification Groups in Childhood Medulloblastoma Using Combined Clinical, Pathologic, and Molecular Variables

David W. Ellison, et al. JCO 29(11):1400,2011

- **Purpose** Medulloblastomas are heterogeneous and include relatively good-prognosis tumors characterized by Wnt pathway activation, as well as those that cannot be successfully treated with conventional therapy. Developing a practical therapeutic stratification that allows accurate identification of disease risk offers the potential to individualize adjuvant therapy and to minimize long-term adverse effects in a subgroup of survivors.
- **Results**
- 1. Metastatic disease and large-cell/anaplastic (LC/A) phenotype were the clinicopathologic variables associated with poor progression-free survival (PFS).
- 2. Nuclear immunoreactivity for β -catenin, *CTNNB1* mutation, and monosomy 6 all identified a group of good-prognosis patients.
- 3. *MYC* amplification was associated with poor outcome, but other CNAs were not.
- 4. Low-risk medulloblastomas were defined as β -catenin nucleopositive tumors without metastasis at presentation, LC/A phenotype, or *MYC* amplification
- 5. High-risk medulloblastomas were defined as tumors with metastatic disease, LC/A phenotype, or *MYC* amplification.
- 6. Low-risk, standard-risk, and high-risk categories of medulloblastoma had significantly ($P < .0001$) different outcomes.

•Medulloblastoma Comprises Four Distinct Molecular Variants

Paul A. Northcott, et al. JCO 29(11):1408, 2011

- **Purpose** Recent genomic approaches have suggested the existence of multiple distinct subtypes of medulloblastoma. We studied a large cohort of medulloblastomas to determine how many subgroups of the disease exist, how they differ, and extent overlap between subgroups.

Results 1. Multiple unsupervised analyses of transcriptional profiles identified the following four distinct, nonoverlapping molecular variants: WNT, SHH, group C, and group D.

2. Supervised analysis of these four subgroups revealed significant subgroup-specific demographics, histology, metastatic status, and DNA copy number aberrations.

3. Immunohistochemistry for DKK1 (WNT), SFRP1 (SHH), NPR3 (group C), and KCNA1 (group D) could reliably and uniquely classify formalin-fixed medulloblastomas in approximately 98% of patients.

4. Group C patients (NPR3-positive tumors) exhibited a significantly diminished progression-free and overall survival irrespective of their metastatic status.

Molecular Characterization of Subtypes

- 1. Studies identify 4-6 subgroups.
- 2. All describe a SHh pathway with high incidence among desmoplastic tumors.
- 3. A Wnt pathway with classic histology affects older children.
- 4. Less favorable subtype associated with MYC over-expression and amplification.
- 5. Likely that tumor suppressors, oncogenes, microRNAs and epigenetic mediators will be identified as we continue to analyze molecular profiles and conduct next generation sequencing.
- 6. Such molecular analysis should ultimately allow targeted therapies directed at the defective pathways.

Monje, M. et al. Hedgehogs, Flies, Wnts and MYCs: The Time Has Come for Many Things in Medulloblastoma JCO 29: 1395, 2011

Editorials

Table 1. Medulloblastoma Subtypes

Characteristic	Wnt	Hh	c-MYC Amplification	Other
Prognosis	Excellent	Good	Dismal	Fair
Demographic				
Age, years	Distributed across ages	Primarily in infants < 3 and adults > 16	Children 3-10	Distributed across ages
Male to female ratio	1:1.7	2:1	1:0.7	1:0.5
Frequency (all ages), %	10	33	27	28
Metastatic disease, %	0	7	75	31
Histologic subtype		Desmoplastic	Anaplastic/large cell	
Genomic abnormality	Monosomy 6		c-MYC amplification	
Elevated gene expression	Wnt pathway c-MYC	Hh pathway n-MYC	Photoreceptor pathways Neuronal differentiation pathways c-MYC	Neuronal differentiation pathways
Immunomarker	DKK1	SFRP1	NPR3	KCNA1

Abbreviation: Hh, Hedgehog.

Medulloblastoma: Driving the Next Generation Clinical Trials

S. Leary and J. Olson *Curr Opin Pediatr* 2012, 24: 33-39

Activating mutations in the WNT pathway represent the WNT subtype [44,48^{***},51,52^{**}]. The identification of nuclear β -catenin has been demonstrated to be nearly 100% specific and sensitive for the presence of mutation and makes it possible to reliably identify WNT

treated with conventional therapy identify this subtype group of patients as ideal candidates for trials of therapy reduction. Targeted therapy against the WNT pathway is also likely to be feasible in the future [54].

Table 1. Summary description of molecular subtypes of medulloblastoma

Molecular subtype	Approximate percentage of patients	Typical patient age	Typical histology	Cytogenetic markers	Molecular markers	Clinical strategy
WNT	10	Older childhood	Classic	Monosomy 6	β -Catenin	Reduction in therapy
SHH	25	Infant and adult	Desmoplastic or classic	9q loss	<i>SFRP1</i> [46 ^{***}] or <i>GAB1</i> [47]	SHH pathway inhibitors
Group C	30	Childhood	Classic or anaplastic	Isochromosome 17q	<i>MYC</i> activation in 50% of this subtype	Intensified therapy, novel therapeutic
Group D	35	Childhood	Classic or anaplastic	Isochromosome 17q	Unknown	Research focus needed

GAB, growth factor receptor-bound protein 2 associated binding protein; MYC, myelocytomatosis; SHH, Sonic Hedgehog; SFRP, secreted frizzled-related protein; WNT, wingless-type murine mammary tumor virus integration site.

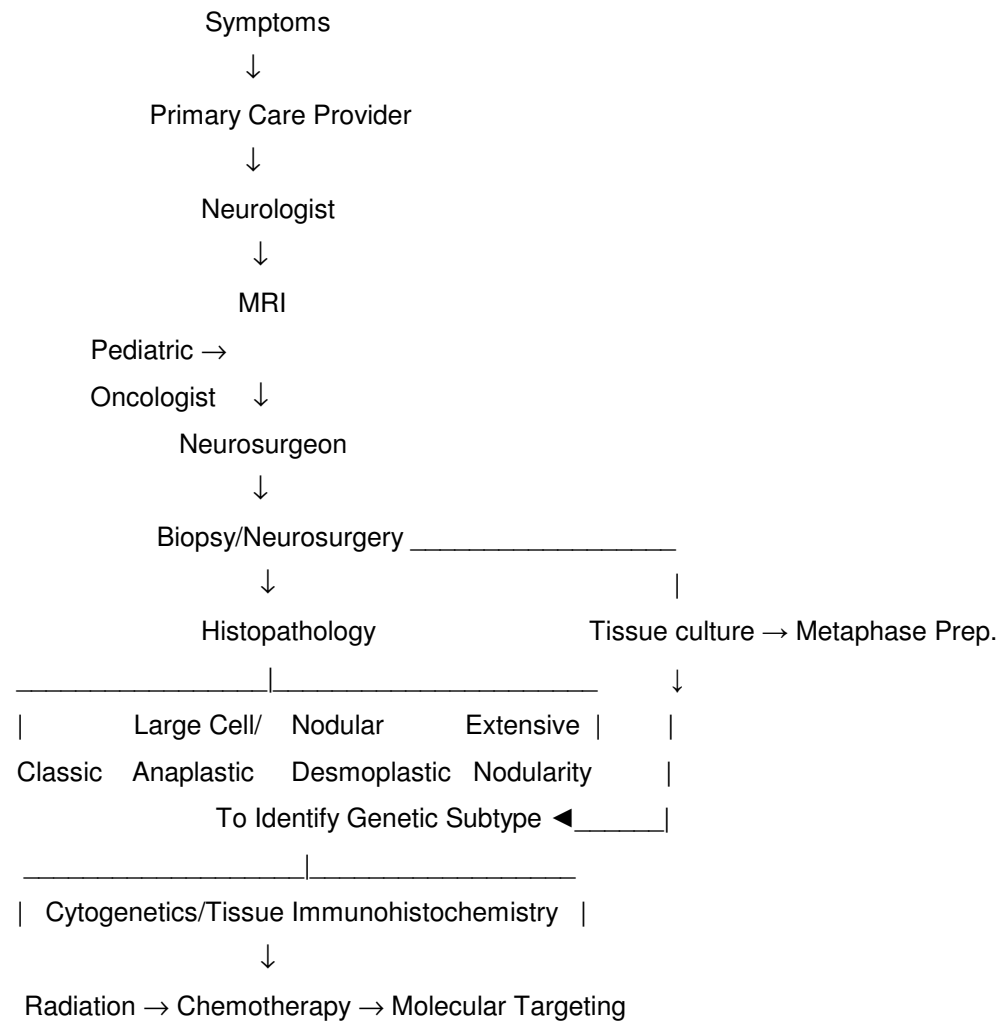
1040-8703 © 2012 Wolters Kluwer Health | Lippincott Williams & Wilkins

www.co-pediatrics.com

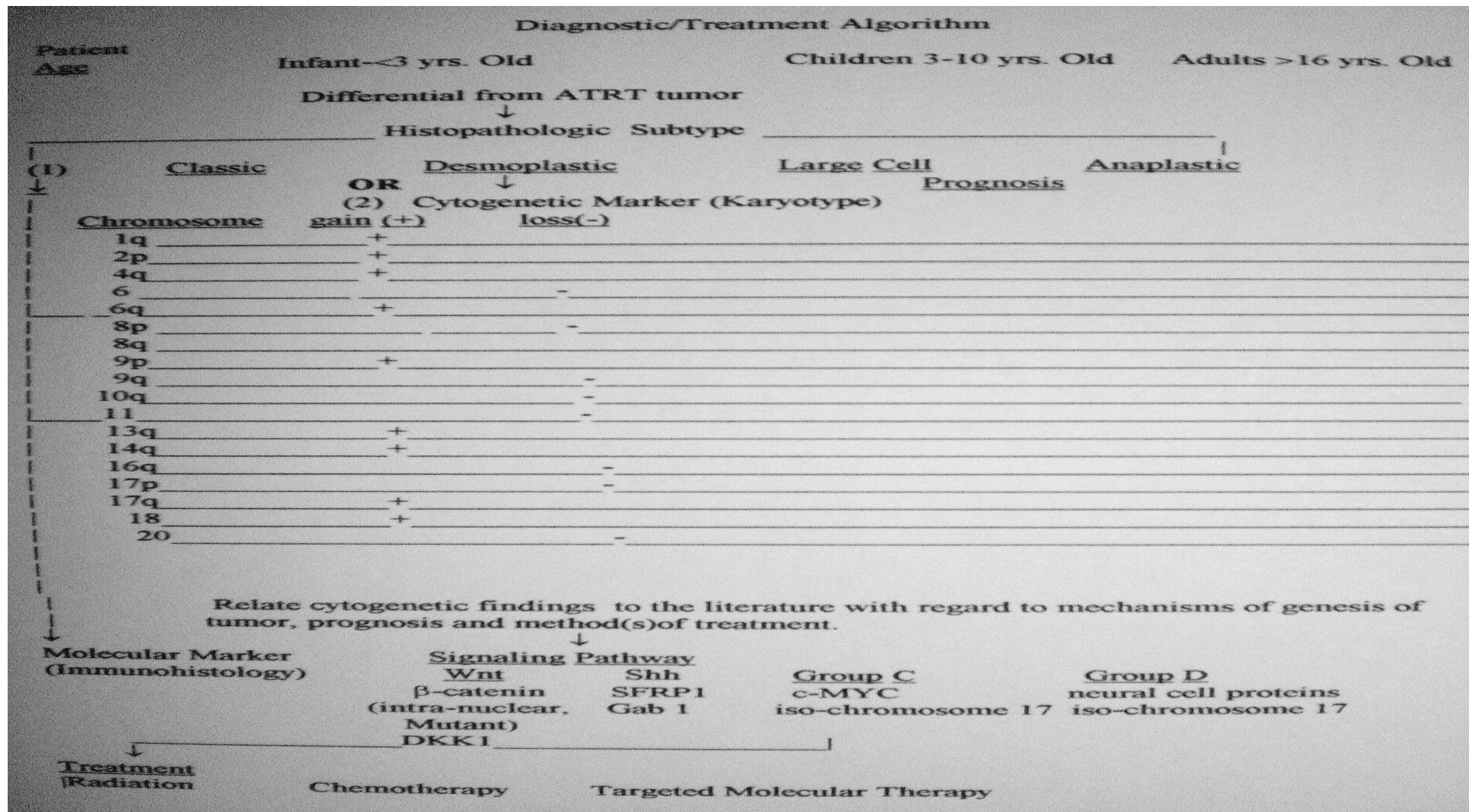
Copyright © Lippincott Williams & Wilkins. Unauthorized reproduction of this article is prohibited.

PTCH1+9q22.3

Medulloblastoma Flow Sheet

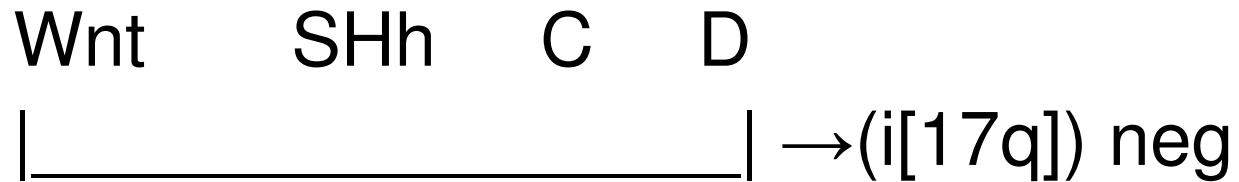

Suggested Diagnostic/Treatment Algorithm



Use of An Algorithm (LOH?)

Classic

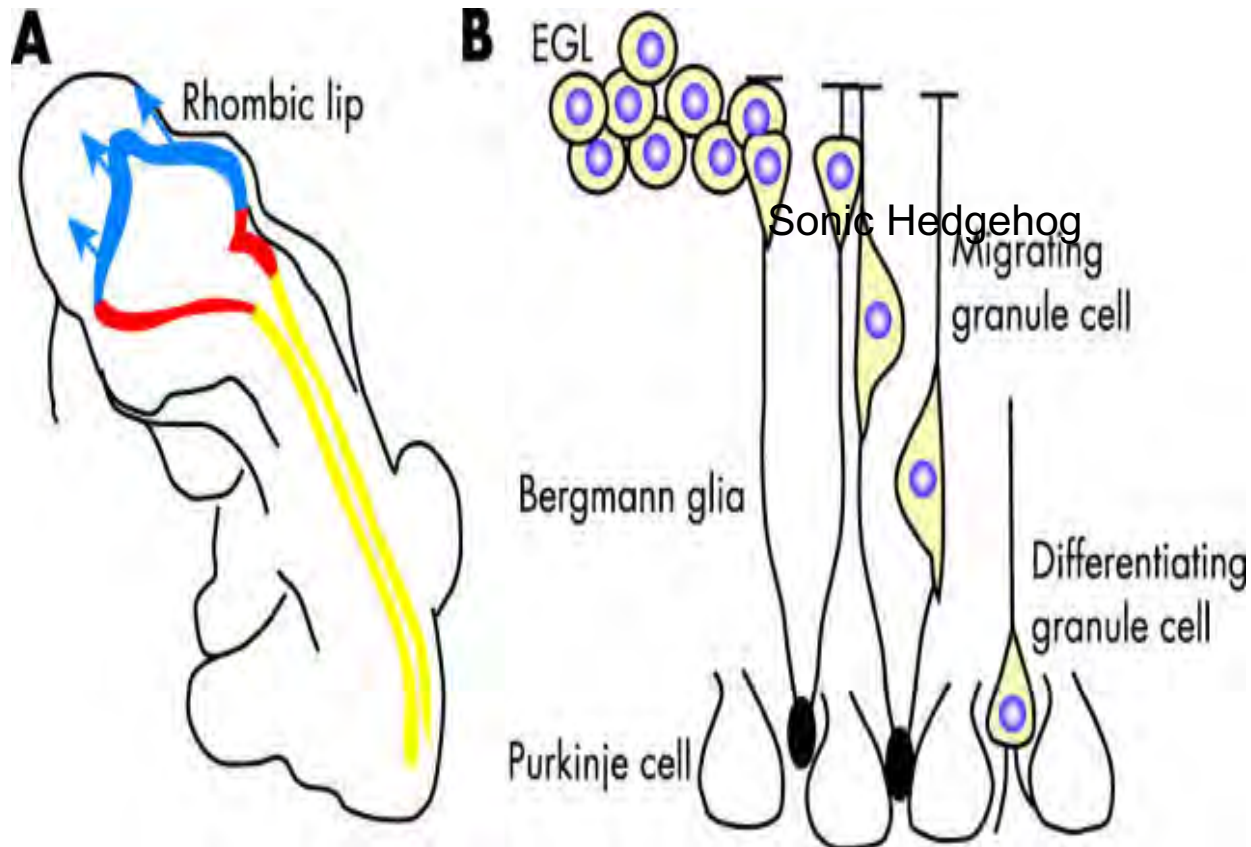


- Wnt ? or SHh?
- ↓ ↓
- * monosomy 6⁻? * loss of 9q⁺?
- ↓ (PTCH1 9q22.3)
- ↓
- β-catenin SFRP
- *tumor suppressor on lost 6⁺?, on lost 9q⁺?

Embryonic Development of Cerebellum-I

- A critical developmental process in cerebellar maturation involves expansion, migration, and differentiation of immature precursor cells from the external granule-cell layer to form the internal granule-cell layer. This process is spatially and temporally regulated by activation of the hedgehog pathway in granule-cell precursor stem cells, in response to SHh produced by the Purkinje cells; as reported in 1999 by Dahmane and Ruiz-i-Altaba

• Embryonic Development of Cerebellum-II



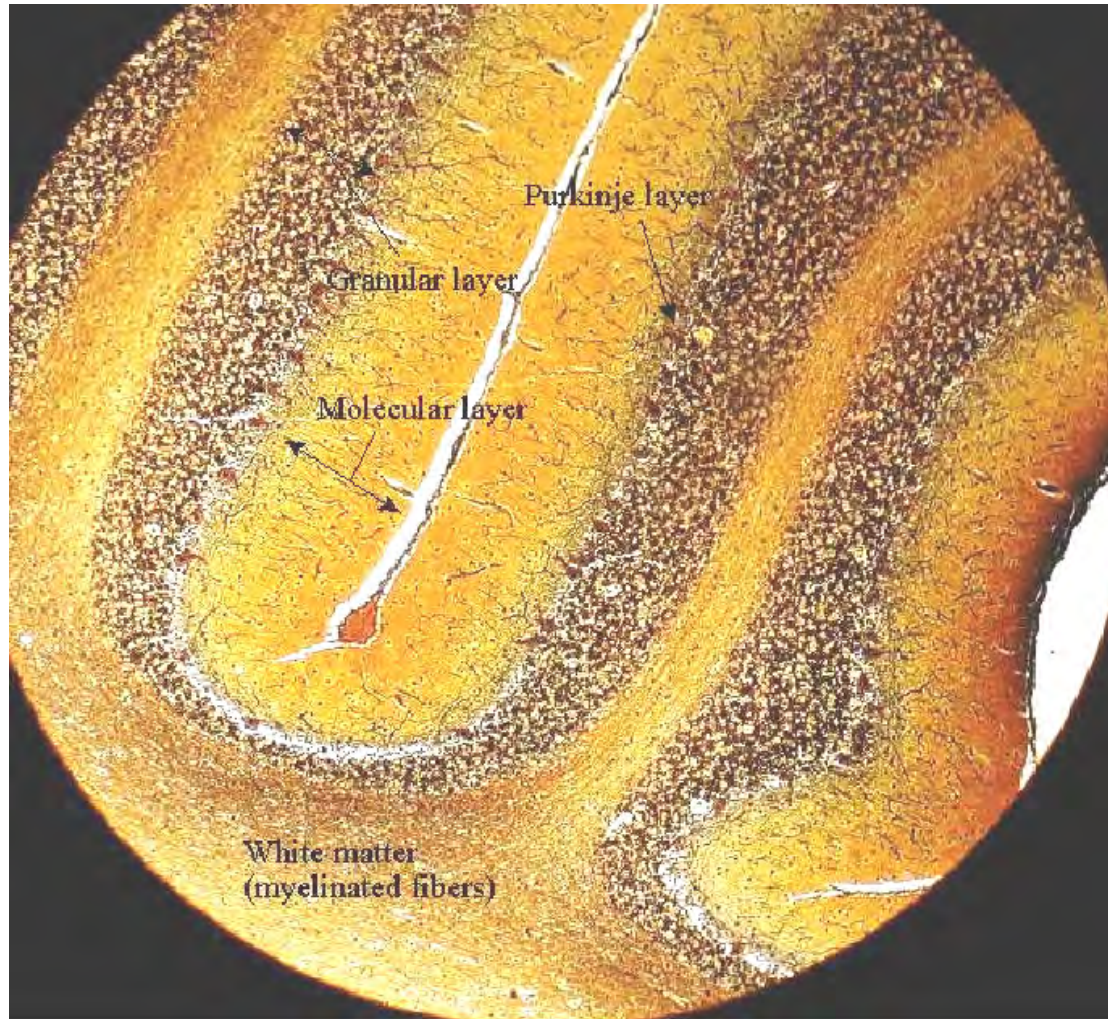
The cerebellum is generated from two distinct progenitor cell populations. (A) The granule cells are produced from progenitor cells that migrate from the rhombic lip early during development. Once they arrive at the developing cerebellum, these cells proliferate extensively to produce the external germinal layer (EGL). (B) After this period of proliferation the granule cell progenitors migrate along the processes of the Bergmann glia and begin to differentiate. Sonic hedgehog secreted by the Purkinje cells regulates the proliferation of the granule cell progenitors in the EGL, which express the hedgehog receptor, patched. Some forms of medulloblastoma are believed to arise from granule cell precursors that have sustained mutations in the hedgehog signalling pathway.

An Hypothesis Regarding Origin of Cerebellum (2009)

- One hypothesis proposes that medulloblastomas have more than one cell of origin. This is based on studies showing differential immunoreactivity to a neuronal calcium-binding protein that is not expressed in the external granular layer and to a beta-tubulin isotype that is expressed in the neuronal cells of the ventricular matrix and external granular layer. Studies suggest that medulloblastoma expression of neurotrophin (NT3) and its cognate receptor, Trk C, not detected in granule cells, may modulate the behavior of these tumors by inducing apoptosis, thereby retarding tumor progression and resulting in a more favorable prognosis.[1]

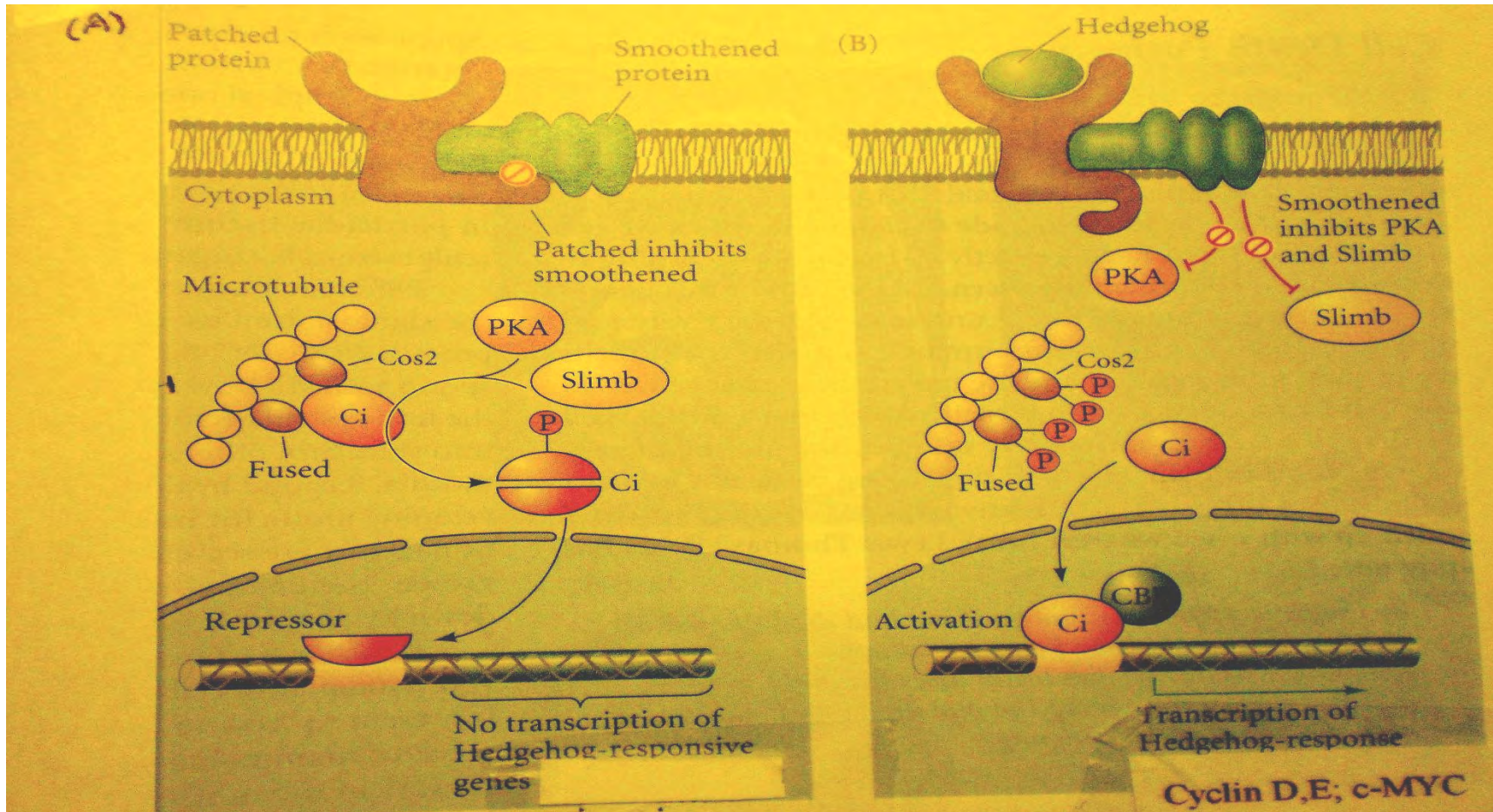
-

Histology of Normal Cerebellum



Reference: From Histology of the Cerebrum and Cerebellum by D. Frankhauser, University of Cincinnati.

Sonic Hedgehog Signaling in Drosophila (Ci=GLI1 in vertebrates)



Reference: Gilbert *ibid.* page 98, figure 3.28 and legend.

Mouse Models

- Although xenograft models in SCID mice have contributed to an understanding of the molecular basis of medulloblastoma, some of the most promising models have been generated from knockout mice carrying targeted deletions in the hedgehog pathway or genes that lead to disruption of hedgehog signaling in granulecell preparations. For example, Patch heterozygous mice develop medulloblastoma, probably as a result of loss of heterozygosity. Although the mechanisms of GLI1 activation may not be the same in mouse models as in humans, the mouse studies lend support to the importance of the hedgehog pathway (at least in some subtypes) in effecting medulloblastoma. Moreover, targeting Gli1 for the treatment of medulloblastoma may be an efficient means of treating the tumor since it lies downstream from possibly diverse upstream events.
- Medulloblastoma is an excellent example of how basic research on the developmental neurobiology of a mouse model combined with studies of human tumors can identify a common target, GLI1, whose targeting may prove useful in cancer treatment. The pathway is crucial in regulating proliferation of EGL progenitor cells in the developing cerebellum; and misregulation of this proliferation could well be integral to production of the tumor.

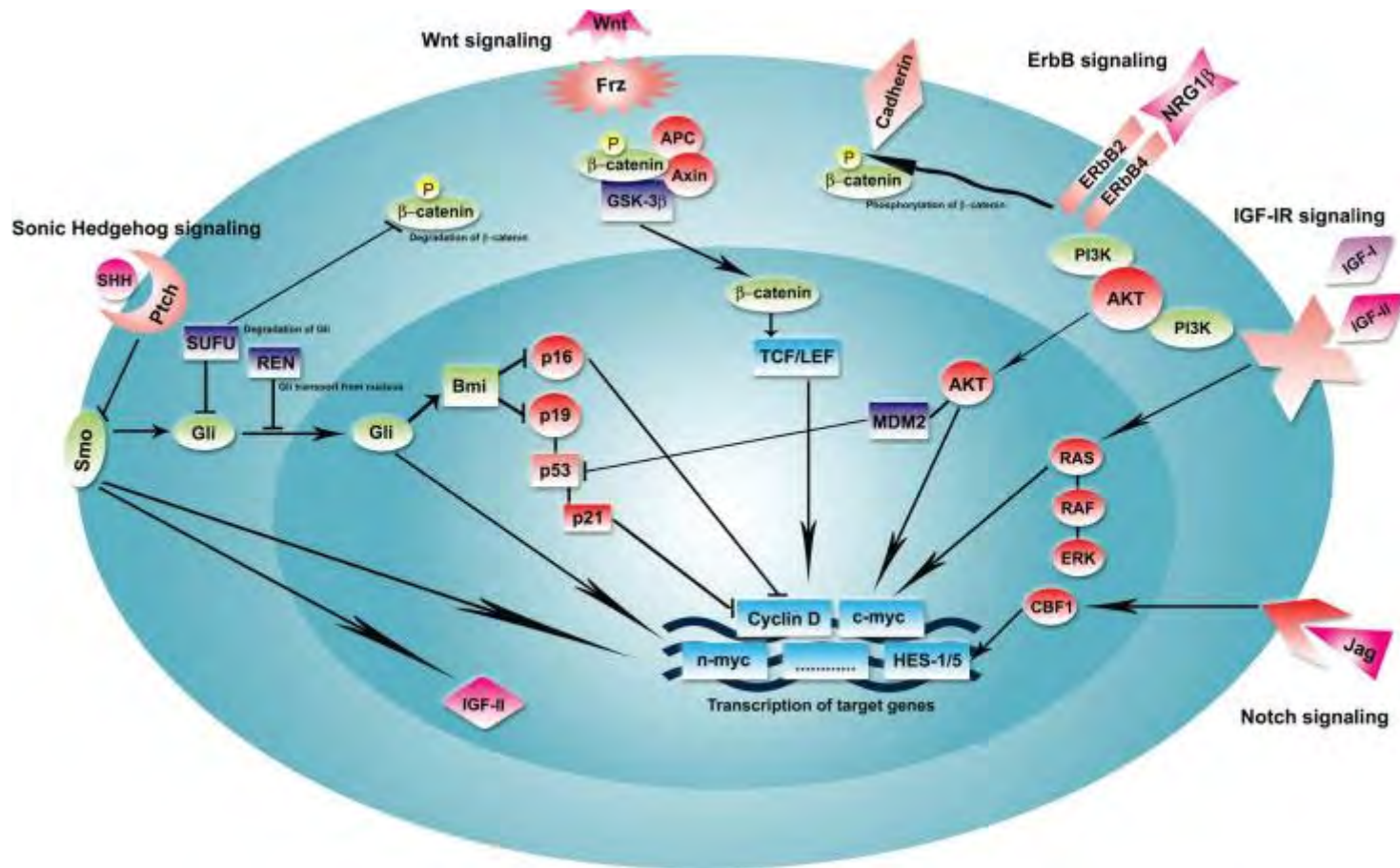
Targeting Medulloblastoma: Small-Molecule Inhibitors of
the Sonic
Hedgehog Pathway as Potential Cancer Therapeutics
Cancer Res.2005;65:4975.

- Here we review our recent demonstration that a small-molecule inhibitor of [Smo] this pathway can regress tumors that arise in a transgenic mouse of medulloblastoma.(Ptc1+/-) These and other findings suggest that inhibitors of Sonic Hedgehog signaling may offer an effective way to target some malignancies.

Inhibition of Sonic Hedgehog Pathway by Vismodegib (A Smoothed Inhibitor)

- Despite the fact that only 15-30% of the human tumors show hedgehog activation, the NCI and Genentech/Curtis have carried out both Phase I and II studies on small numbers of tumor-bearing patients: at the dosages used with pediatric patients, no significant side effects (but no sustained efficacy) were observed; with 1 adult patient, the tumors initially appeared to respond to the drug treatment but then became resistant in relation to a mutation in the Smoothed receptor. Since other pathways can cause the tumor, use of the drug should be limited to tumors that provide evidence that the sonic hedgehog pathway has been activated.

deBont, J. et al. Biological Background of Pediatric Medulloblastoma and Ependymoma: A Review from a Translational Research Perspective Neuro Oncol 10: 1040, 2008

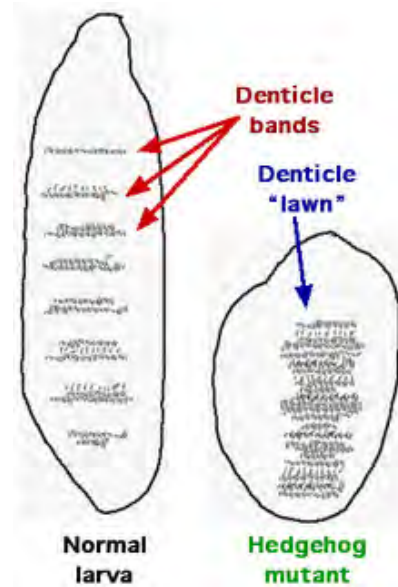


Origin of the name “Hedgehog”

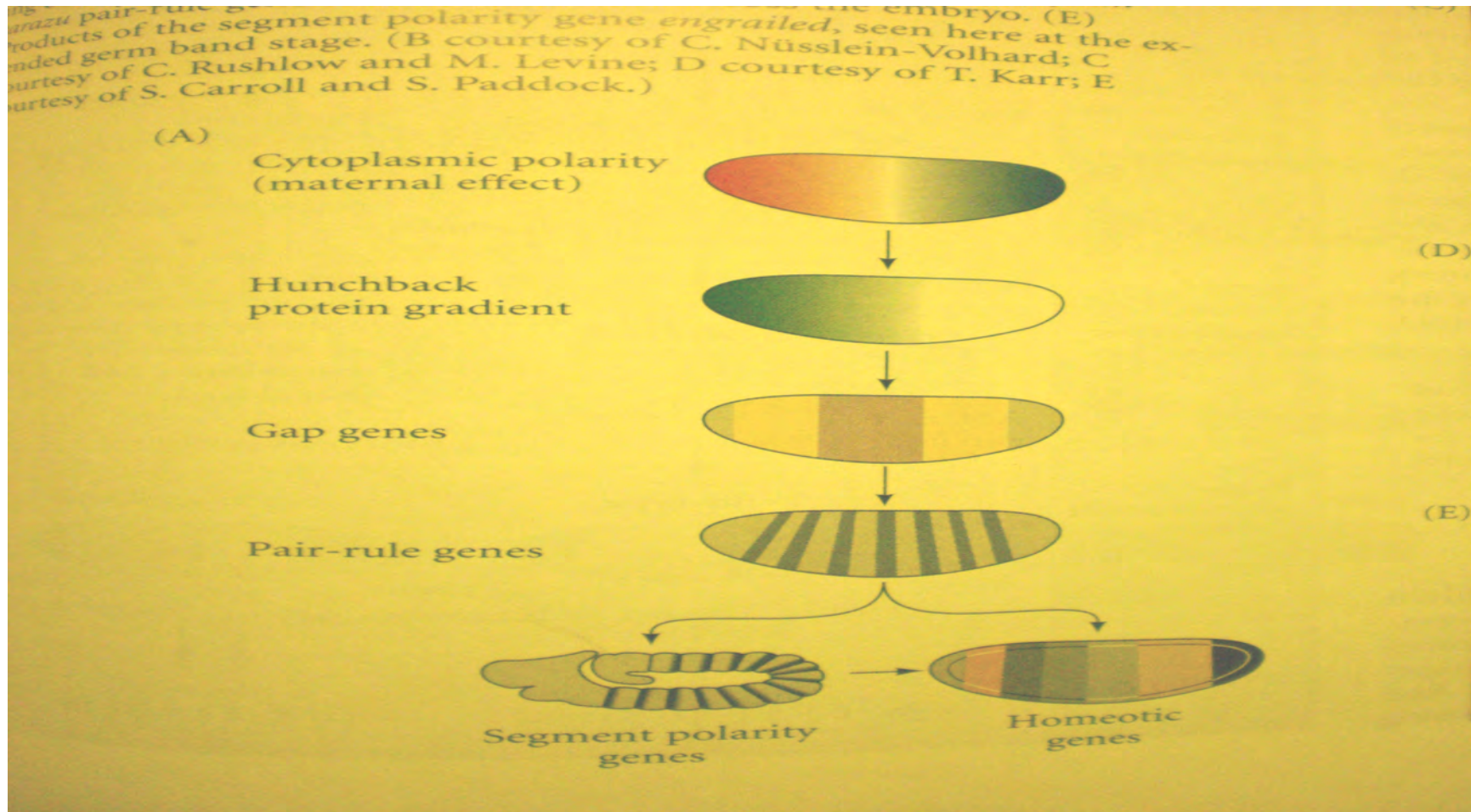
In the 1970s, a fundamental problem in developmental biology was to understand how a relatively simple egg can give rise to a complex segmented body plan. In the late 1970s Christiane Nüsslein-Volhard and Eric Wieschaus isolated mutations in genes that control development of the segmented anterior-posterior body axis of the fly; [3] their "saturation mutagenesis" technique resulted in the discovery of a group of genes involved in the development of body segmentation. In 1995, they shared the Nobel Prize with Edward B. Lewis for their work studying genetic mutations in *Drosophila* embryogenesis. [4] The *Drosophila* hedgehog (*hh*) gene was identified as one of several genes important for creating the differences between the anterior and posterior parts of individual body segments. Some hedgehog mutants result in abnormally-shaped embryos that are unusually short and stubby compared to wild type embryos. The function of the hedgehog segment polarity gene has been studied in terms of its influence on the normally polarized distribution of larval cuticular denticles as well as features on adult appendages such as legs and antennae. [5] Rather than the normal pattern of denticles, hedgehog mutant larvae tend to have "solid lawns" of denticles .

The appearance of the stubby and "hairy" larvae inspired the name 'hedgehog'

Appearance of the Mutant Sonic Hedgehog Drosophila Larva



Stages of Larval Development



Rugs with "Drosophila" Larval Patterns

Pair Rule -Determined Stripes



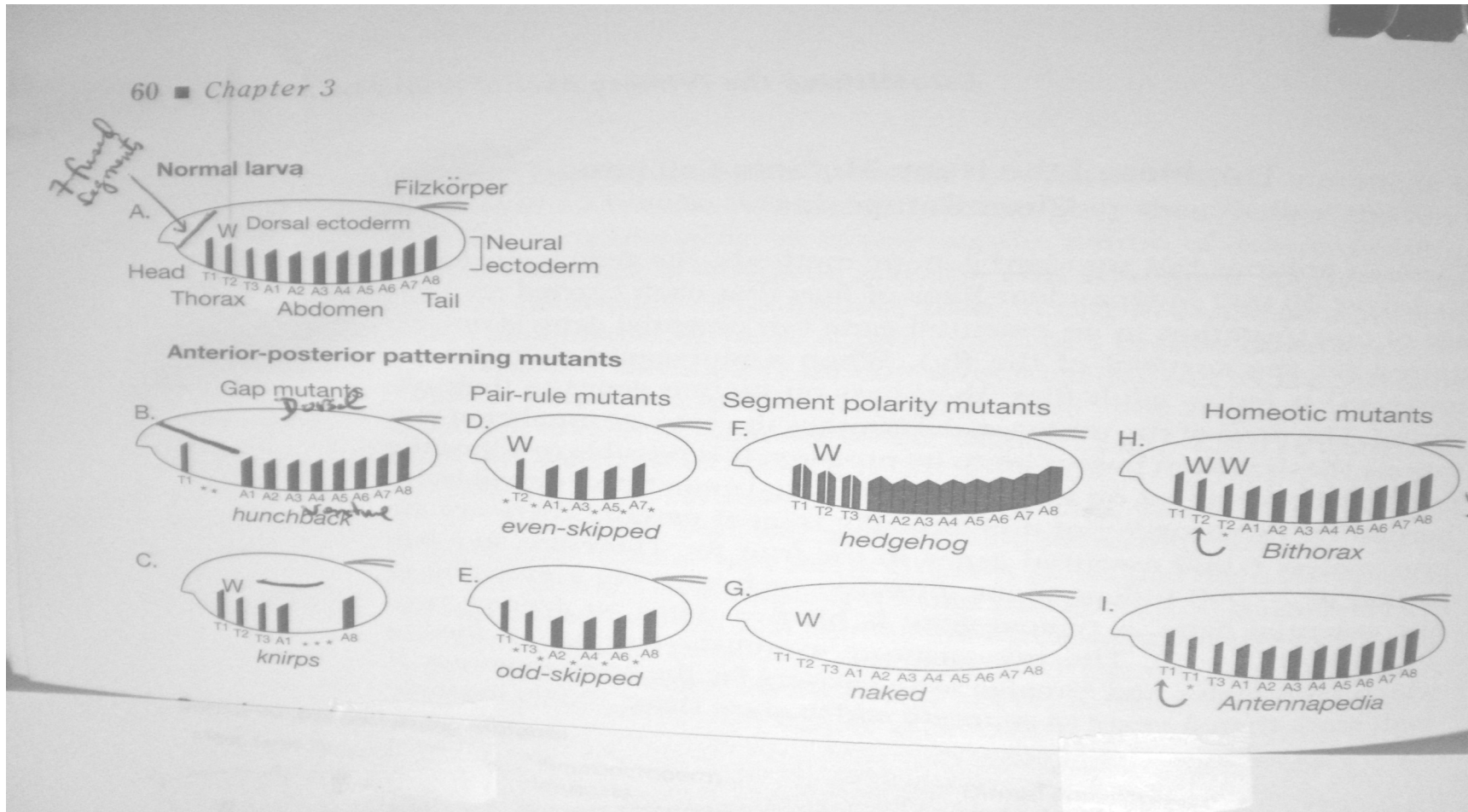
Segment Polarity Stripes



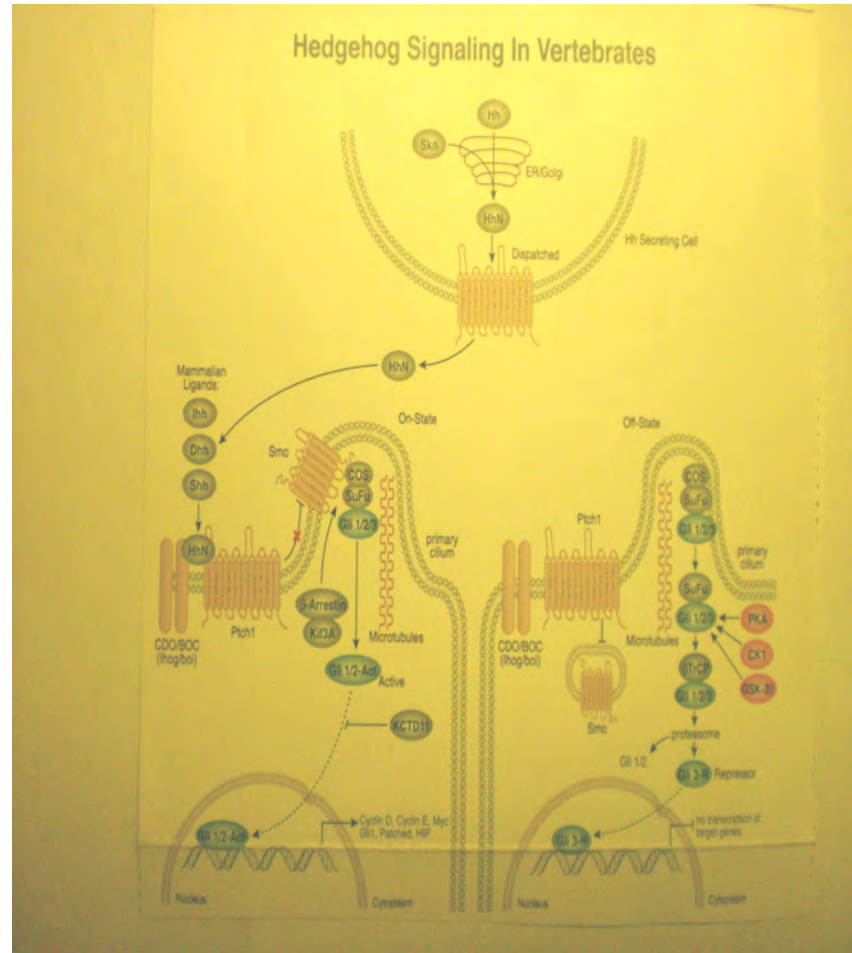
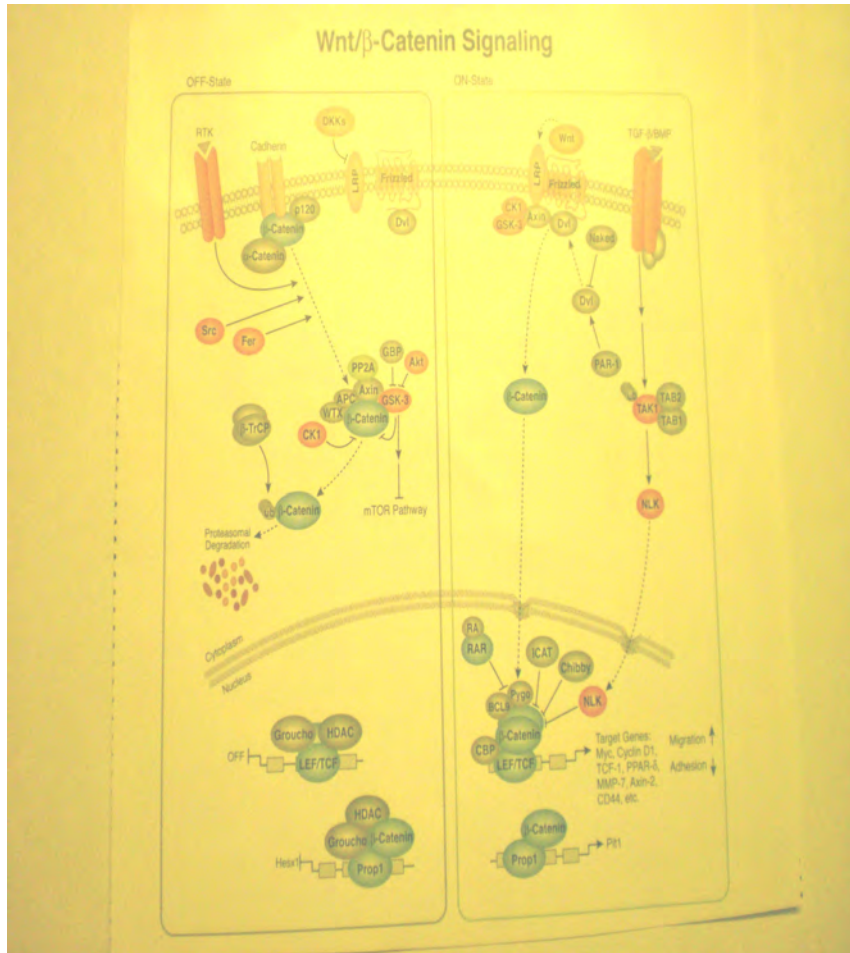
Homeotic Genes



Effects of Specific Mutations within Stages

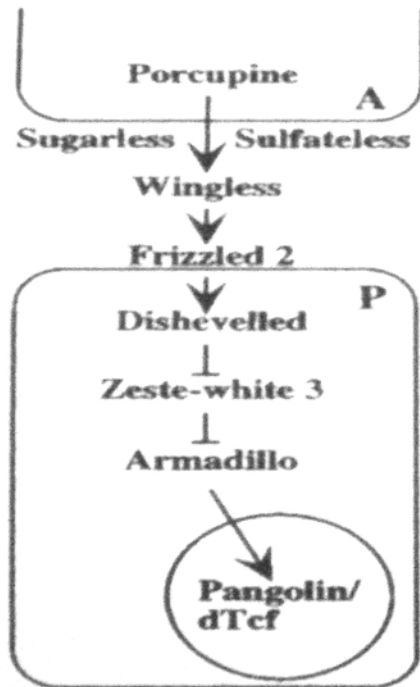


Signaling by Wnt and SHh Pathways

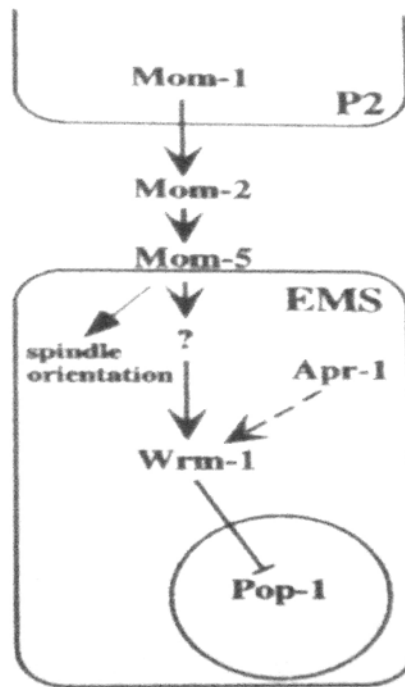


Wnt Signaling Pathway is Conserved from *Drosophila* to Vertebrates (Man)

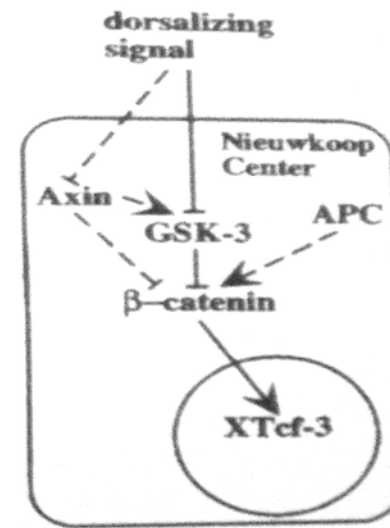
62 WODARZ & NUSSE



segment polarity
Drosophila



gut development
C. elegans



axis formation
Xenopus

Gibson P, Tong Y, Robinson G, et al. Subtypes of medulloblastoma have distinct developmental origins. Nature 2010; 468:1095

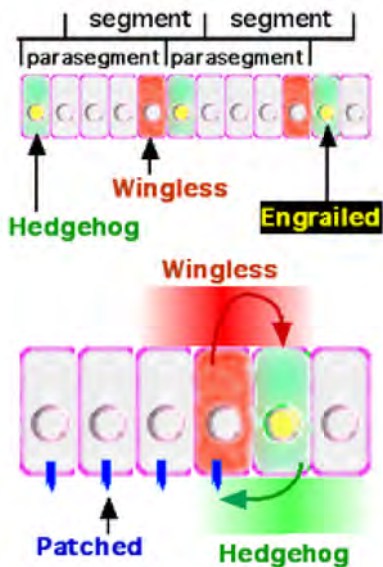
- This article describes the first genetically engineered mouse model of the WNT subtype of medulloblastoma. The creation of this model and comparative description of the precise location of human WNT subtype medulloblastoma in comparison with SHH subtype medulloblastoma suggests that the molecular subtypes of medulloblastoma arise from distinct cells of origin

Gibson et al. Continued

Here we provide evidence that a discrete subtype of medulloblastoma that contains activating mutations in the WNT pathway effector *CTNNB1* (hereafter, WNT subtype)1, 3, 4 arises outside the cerebellum from cells of the dorsal brainstem. We found that genes marking human WNT-subtype medulloblastomas are more frequently expressed in the lower rhombic lip (LRL) and embryonic dorsal brainstem than in the upper rhombic lip (URL) and developing cerebellum

Reciprocal interactions of SHh and Wnt in Drosophila

- Cells with Hh-activated Patched receptor synthesize the **Wingless** protein which feeds back to bind to the Frizzled receptor to cause synthesis of more SHh.



Take Home Lessons

- 1. Oncodevelopmental deregulation of signaling pathways (SHh and Wnt) otherwise essential in brain development has important role in causing medulloblastoma.
- 2. Medulloblastoma is heterogenous: Distinct subtypes of the tumor occur; and "one size does not fit all": Subtypes require treatment as relates to mechanism: a corollary-
- 3. Clinical trials of drugs should be with known individual subtypes; not with mixtures of subtypes even if they share the same histology.
- 4 Genetic mechanisms are tightly-conserved from invertebrates to vertebrates. Studies in *Drosophilla* and mice yield information relevant to diagnosis and treatment of disease in humans.
- Quid est Demonstratum!



Relieve suffering

Identification of isochromosome 17 (i[17q])

- Isochrome 17q can be detected by use of a centromeric alpha satellite DNA probe.



• Molecular Characterization of Subtypes

What has emerged is a series of studies that identify four to six subgroups of medulloblastoma on the basis of molecular differences [10-12]. Despite the disparity in the number of subtypes, there is a lot of common ground among the studies. All describe a subtype with aberrant Sonic Hedgehog pathway signaling (often *PTCH1* mutations), which has a high incidence amongst desmoplastic tumors [10-12]. Another subtype has aberrant signaling in the Wingless (WNT) pathway (frequently *CTNNB1* mutations), a classic histology that commonly affects older children [5,10-12]. Additionally, a less favorable subtype emerged from the latest studies [12], which associates *MYC* overexpression and amplification with prognostic features (i.e., high prevalence of metastatic disease and large-cell anaplastic histology). All these subtypes have correlations with the histologic variants (i.e., the Sonic Hedgehog subtype are largely desmoplastic tumors and the *MYC* subtype are frequently large-cell anaplastic tumors), so the molecular profiling of these tumors should reduce the inconsistencies between different pathologists' interpretations. Signaling pathways that promote growth (e.g., Sonic Hedgehog, WNT, Notch, Hippo, and IGF/PI3K) or suppress proliferation (e.g., BMP2, BMP4, and BMP7) can now be analyzed by subtype [13,14]. Furthermore it is likely that tumor suppressors, oncogenes, microRNAs, and epigenetic mediators will be identified as we continue to analyze the molecular profile and conduct next generation sequencing on an increasing number of tumors. Such molecular analysis of tumors should ultimately allow targeted therapies directed at the defective pathway.

Traditional Subtypes Based on Histopathology

- 1. **Classic** (80%) Small, symmetrical nuclei; cells in layers or sheets.
- 2. **Desmoplastic** Clusters of cells surrounded by collagen rich tissue. Nodules have characteristics of early differentiation based on morphological/molecular features.
- 3 **Large Cell** Relatively high ratio of cytoplasm to nucleus; anaplasia.
- 4. **Melanotic** Produces melanin.
- 5 **Medullomyoblastoma** produces muscle proteins.